
بسم الله الرحمن الرحيم

MALE INFERTILITY

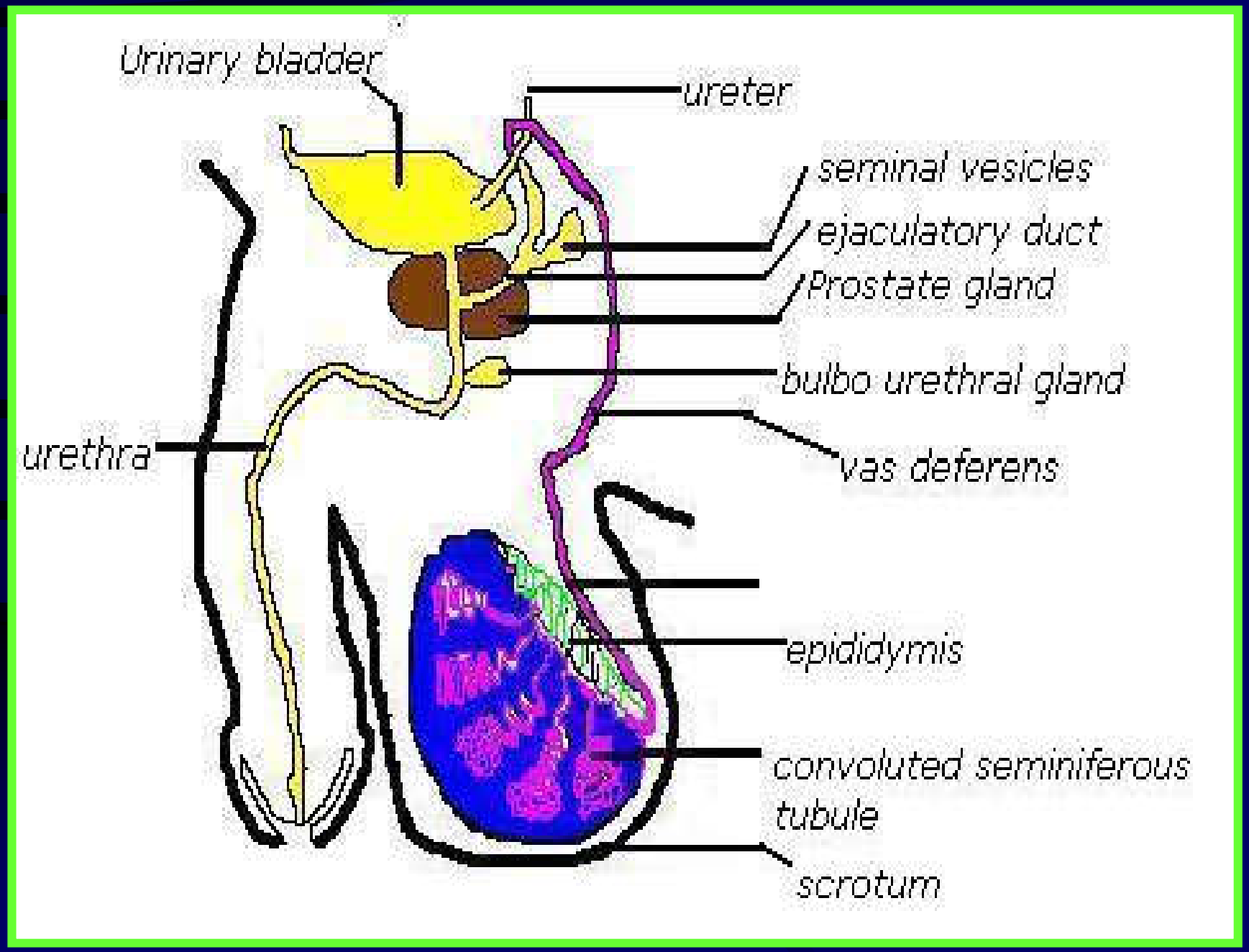
Urinary bladder
ureter
seminal vesicles
ejaculatory duct
Prostate gland
bulbo urethral gland
urethra
vas deferens
epididymis
convoluted seminiferous tubule
scrotum

Definition:

Failure of conception after at least a year of regular unprotected intercourse

Primary infertility:

When the man has never impregnated a woman before

Secondary infertility:

When the man has impregnated a woman before

Etiology of male infertility

A) Functional causes :

1. Chromosomal anomalies e.g Klinefelter's Syndrome (47 xxy)
2. Sertoli cell only Syndrome
3. Undescended testis
4. Varicocele
5. Hypogonadism and hyperprolactinemia
6. Post-pubertal mumps & leprosy orchitis
7. Chemical e.g cancer chemotherapeutics
8. Irradiation
9. Excessive heat exposure
10. Idiopathic

B) Obstructive causes:

1. Congenital bilateral absent of V.D
2. Post inflammatory e.g Bilharziasis, TB and gonorrhoea
3. Surgical trauma with vasectomy e.g herniorrhaphy

Diagnosis of male infertility

A) History and clinical examination:

1- History:

- 1ry or 2ry infertility
- Duration and regularity of marriage
- Sexual and ejaculatory function
- Fever during past 6 months
- Chronic diseases e.g. T.B., D.M.
- Hormonal treatment
- Chemotherapy, radiotherapy or surgery

2- Clinical examination:

*** General:** **2ry sexual characters or gynaecomastia**

*** Local:**

- Penis for ulceration, hypo- or epispadius
- Testis for size, consistency and descent
- Epididymis for nodules or cysts
- Spermatoc cord for varicocele (grades)
- Prostate by PR

B) Investigations:

- Semen analysis
- Hormonal assay (FSH, LH, testesterone & prolactin)
- Scrotal U/S to detect Varicocele
- Transrectal ultrasonography to study the prostate, seminal vesicles and ejaculatory ducts
- Chromosomal study (Klinefelter's Syndrome)
- Testicular biopsy, to differentiate between functional & obstructive azoospermia

مستشفى سوهاج الجـامعي
قسم الأمراض الجلدية والتناسلية

(1999)

STANDARD SEMEN ANALYSIS

NAME:.....DATE: .....
ABSTINENCE PERIOD: .....
METHOD OF OBTAINING SPECIMEN:.....

Physical characters

1-Coagulum:.....(Present in fresh semen)
2-Liquefaction time:.....(10-20 minutes)
3-Volume:.....(2-6 ml)
4-Colour:.....(Translucent to whitish gray)
5-Odour:.....(Characteristic)
6-Consistency:.....(Threading not more than 2 cm)
7-Reaction:.....(Alkaline, pH 7.2-7.8)

Microscopic characters

1-Sperm concentration:.....(20-250 million /ml)
2-Total sperm count:.....(40 million or more)
3-Sperm motility:(*A*: 25%or *A*&*B*: 50% or more within 60 minutes)
A: rapid linear forward motility.....
B: slow linear and non linear progression.....
C: non-progression motility.....
D: immotile.....
4-Normal sperm forms:.....(≥50%)
5-Agglutination:.....(≤10%)
6-Round cells:.....(0-10/HPF)
8-Others:.....

مستشفى سوهاج الجامعي
قسم الأمراض الجلدية والتناسلية

STANDARD SEMEN ANALYSIS
(WHO 2010)

NAME:… …… DATE: ……... ...……..……..…
(2-7 days) **ABSTINENCE PERIOD:**
METHOD OF OBTAINING SPECIMEN:……

Physical characters

1-Coagulum:…… (Present in fresh semen)
2-Liquefaction time:…… (Within 15 minutes)
3-Volume:…… 1.5ml (1.4-1.7)
4-Colour:…….....(Translucent to whitish gray)
5-Odour:…… (Characteristic**)**
6-Consistency:…… (Threading not more than 2 cm)
7-Reaction:…… (Alkaline, pH ≥7.2)

Microscopic characters

1-Sperm concentration:…… 15million /ml (12-16/ ml)
2-Total sperm count:… …….. 39 million /ejaculate (33- 46)
3-Sperm motility:
Progressive motility(PR %): …….. 32% (31-34)
Total motility (PR+NP %)…… …… 40% (38-42)
Immotile……..
4-Normal sperm forms :…… 4% (3-4)
5-Agglutination:…… … (≤10%)
6-Round cells:…… (< 1 million)
7-Others:……..
***Remarks*:**

Semen analysis

- **Abstinence period**: 3-5 days
- **Method of collection**: Masturbation
- **Volume:** 2-6 ml
- **Liquefaction time:** 15-60 minutes
- **Consistency:** The length of the thread should not exceed 2cm
- **Appearance:** Characteristic color and odour

Semen analysis

- **PH:** Alkaline (6.8 – 7.2)
- **Motility:** 50% or more rapid & slow progressive motility
- **Count:** 20-250 million/ml
- **Abnormal forms:** Should not exceed more than 50%
- **WBCs:** Less than 1 million/ml
- **RBCs:** Absent

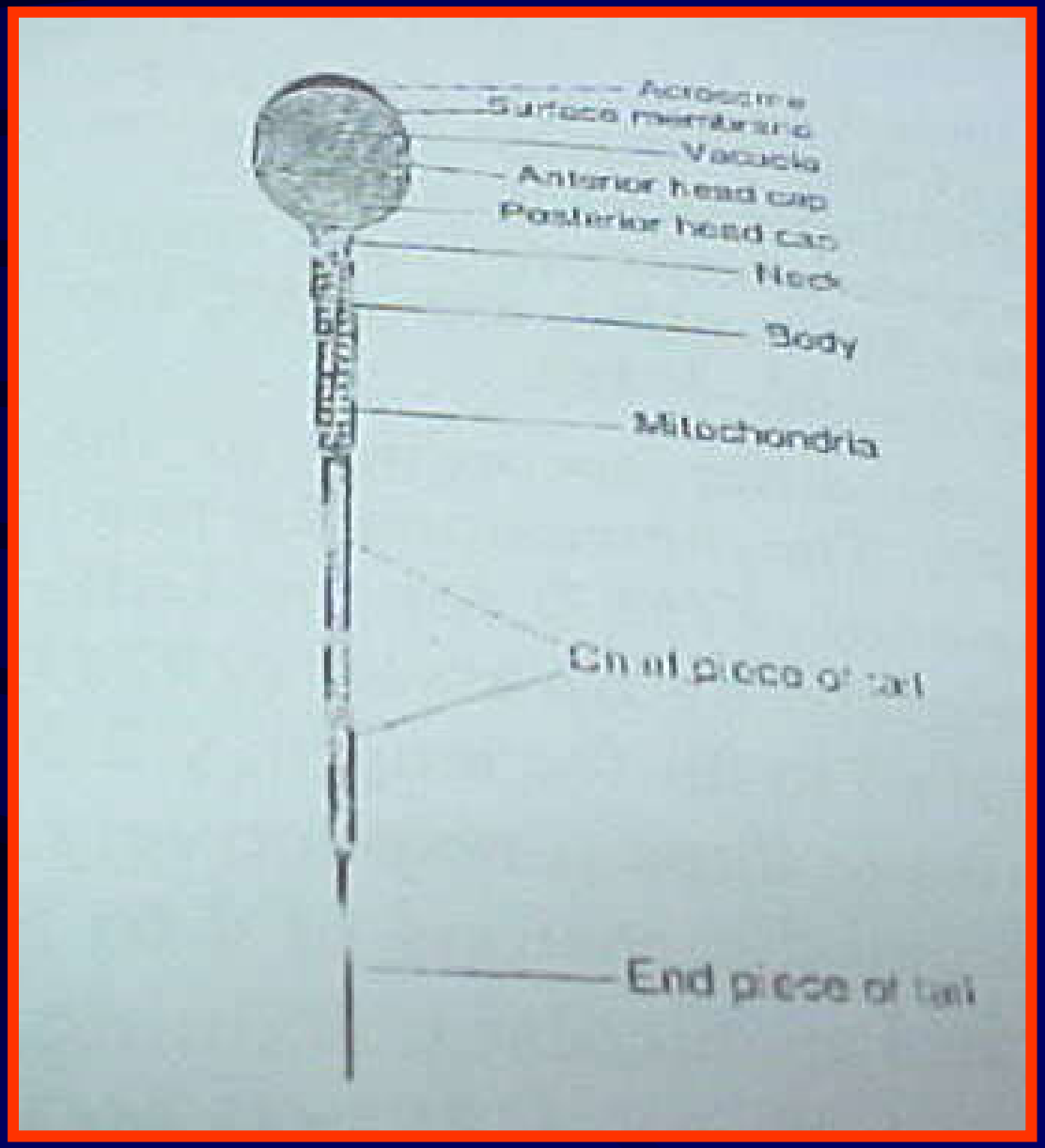
Acrosome
Surface membrane
Vacuole
Anterior head cap
Posterior head cap
Neck
Body
Mitochondria
End piece of tail

Semen abnormalities

- **Aspermia:** No ejaculate
- **Hypospermia:** Semen volume less than 2ml
- **Hyperspermia:** Semen volume more than 6ml
- **Azoospermia:** No sperms in the ejaculate after centrifugation
- **Oligozoospermia:** Sperm count less than 20 millions
- **Asthenozoospermia:** Less than 50% of sperms have progressive motility

Semen abnormalities

- **Teratozoospermia: Abnormal forms more than 50%**
- **Necrozoospermia: All sperms are dead**
- **Pyospermia: Pus cells more than 1 million /ml**
- **Hemospermia: Presence of RBCs**

- Varicocele may lead to stress pattern (OAT, Oligo-astheno-terato-zoospermia)

Treatment of male infertility

A) Medical treatment:

- Replacement therapy by FSH & LH to treat hypogonadotrophic hypogonadism
- Bromocriptine to treat hyperprolactinemia
- Treatment of immunological infertility and infections
- Non-specific treatment by antiestrogen (clomiphene citrate), antioxidants or vitamins

B) Surgical Treatment:

- Varicocelectomy for the Varicocele
- Epididymovasostomy for epididymal obstruction

C) Assisted Reproductive Technologies (ART):

- **Artificial Insemination using Husband's semen (AIH)**
- **In Vitro Fertilization (IVF)**
- **Intracytoplasmic Sperm Injection (ICSI)**

- ICSI can help many of those previously considered hopeless:

1. **Severe cases of oligo-asthenozoospermia**
2. **Obstructive azoospermia**
3. **Azoospermic patients with focal spermatogenesis**

THANK YOU