ABNORMAL UTERINE ACTION

BY

MAGDY ABDELRAHMAN MOHAMED

LECTURER OF OB/GYN

2020

NORMAL UTERINE CONTRACTION

- Regular interval.
- Interval gradually shortens.
- Intensity gradually increases.
- Discomfort in the back and abdomen.
- Associated with cervical dilatation.
- Discomfort not relieved by sedation.

NORMAL UTERINE CONTRACTION

- **POLARITY OF UTERUS:**
  - When upper segment contracts, lower segment relaxes.
- **PACEMAKERS:**
  - Two pacemakers situated at each cornua of uterus generating the contraction in co-ordinated manner.

Uterus polarity

Fundus - strong contraction

↓

Uterine body - weaker contraction

↓

Lower segment - relaxation

NORMAL UTERINE CONTRACTION

- **BASAL TONE:** 5-20 mmHg.
- **PEAK PRESSURE:** around 60 mm Hg pressure.
- **FREQUENCY OF CONTRACTION:** Adequate uterine contractions are 1 in 3 minutes lasting for 45 seconds with good relaxation in between.

ASSESSMENT OF UTERINE CONTRACTION

- CLINICAL PALPATION.
- EXTERNAL TRANSDUCER.
- INTRAUTERINE PRESSURE CATHETER.

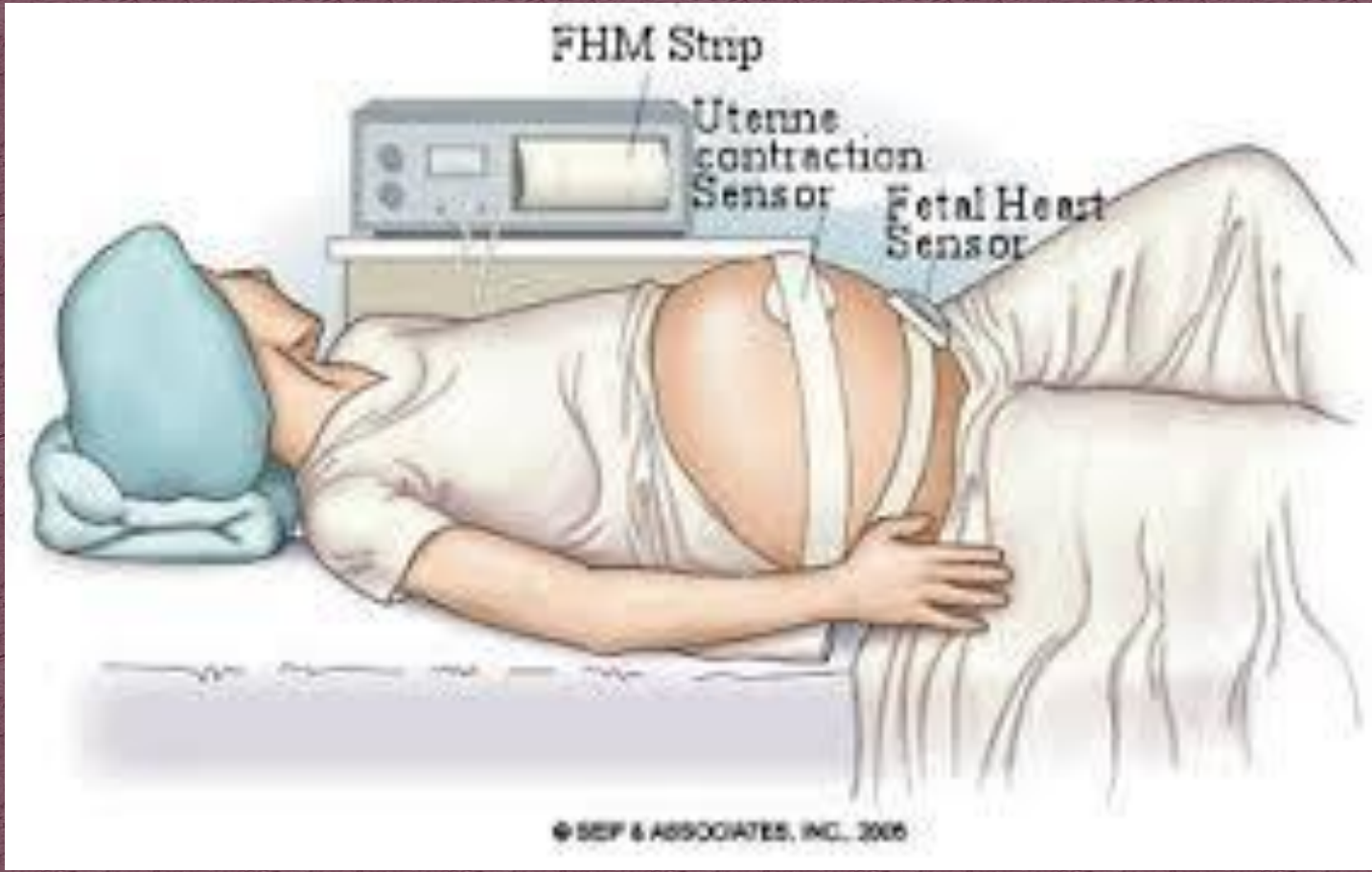
FHM Strip
Uterine contraction Sensor
Fetal Heart Sensor
© SEF & ASSOCIATES, INC. 2006

CLASSIFICATION

- **Normal polarity**
  - Hypertonic dysfunction
    - **Precipitate labour:** in the absence of obstruction
    - **Tonic contraction & retraction (bandls ring):** in presence of obstruction.
  - Hypotonic dysfunction (uterine inertia).
- **Abnormal polarity.**
  - Hypertonic uterine inertia.
  - Contraction ring.
- **Cervical dystocia.**

PRECIPITATE LABOUR

- **Def:**
  - Rate of cervical dilatation greater than 5cm/H in primipara & 10 cm/H in multipara.

- **Risks:**
  - Laceration of cervix & perineum.
  - Postpartum Hge & sepsis.
  - Fetal trauma.

PRECIPITATE LABOUR

Management

- **After delivery:**
  - Examination of birth canal for tear.
- **Subsequent pregnancies:**
  - Hospital admission of mother before delivery.

CLASSIFICATION

- **Normal polarity**
  - Hypertonic dysfunction
    - **Precipitate labour:** in the absence of obstruction
    - **Tonic contraction &retraction(bandls ring):** in presence of obstruction.
  - Hypotonic dysfunction (uterine inertia).
- **Abnormal polarity.**
  - Hypertonic uterine inertia.
  - Contraction ring.
- **Cervical dystocia.**

TONIC CONTRACTION & RETRACTION(BANDLS RING)

Physiological Retraction Ring

- It is a line of demarcation between the upper and lower uterine segment present during normal labour and cannot usually be felt abdominally.

PATHOLOGICAL RETRACTION RING (BANDL'S RING)

* It is the rising up retraction ring during obstructed labour due to marked retraction and thickening of the upper uterine segment while the relatively passive lower segment is markedly stretched and thinned to accommodate the fetus.
* The **Bandl's ring** is seen and felt abdominally as a transverse groove that may rise to or above the umbilicus.

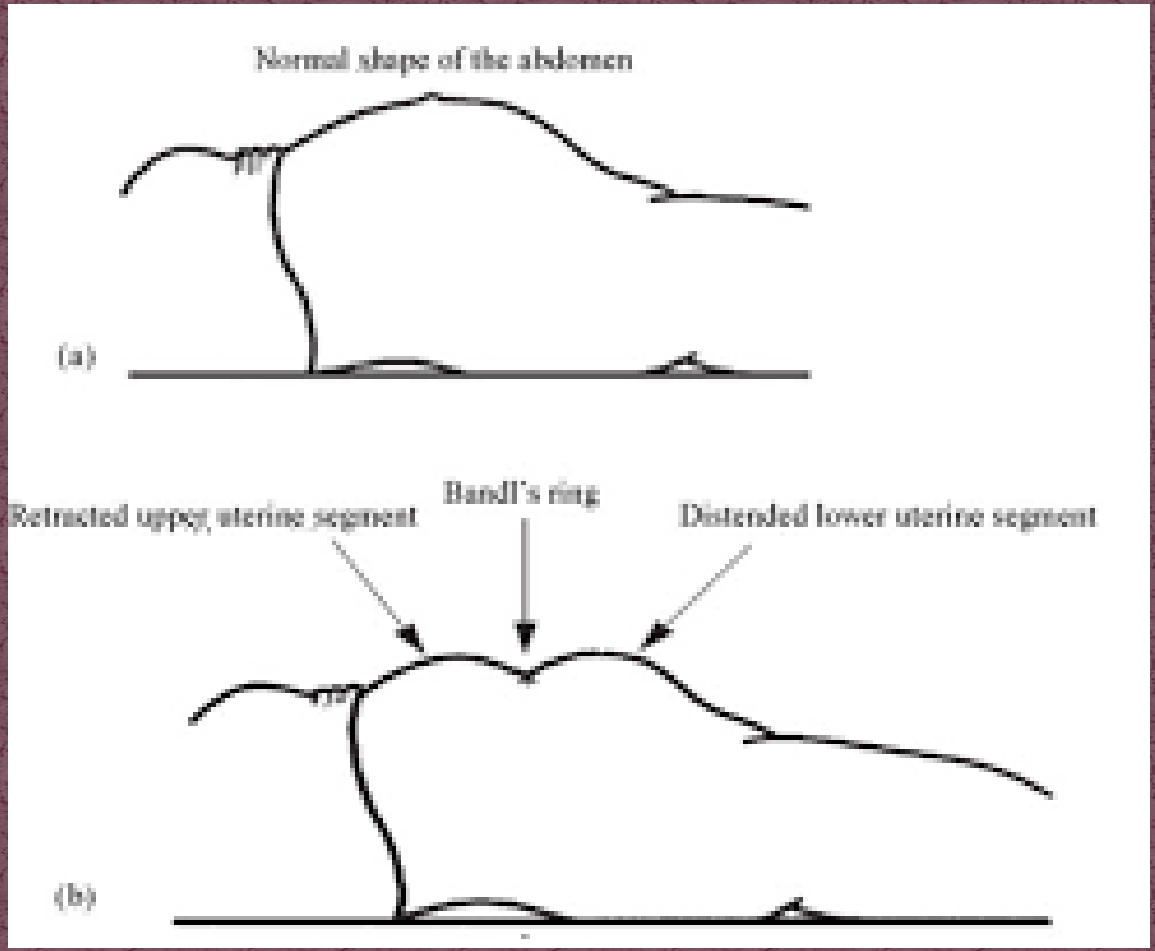
Normal shape of the abdomen
(a)
Retracted upper uterine segment
Bandl's ring
Distended lower uterine segment
(b)

PATHOLOGICAL RETRACTION RING (BANDL'S RING)

- **Clinical picture:** is that of obstructed labour with impending rupture uterus .
- Obstructed labour should be properly treated otherwise the thinned lower uterine segment will rupture.

CLASSIFICATION

- **Normal polarity**
  - Hypertonic dysfunction
    - **Precipitate labour:** in the absence of obstruction
    - **Tonic contraction &retraction(bandls ring):** in presence of obstruction.
  - **Hypotonic dysfunction (uterine inertia).**
- **Abnormal polarity.**
  - Hypertonic uterine inertia.
  - Contraction ring.
- **Cervical dystocia.**

HYPOTONIC UTERINE INERTIA

- Dystocia: abnormal or difficult labour. It characterized by slow progress or arrest of labour.
- Causes:
  - Power (contractions & bearing down).
  - Passenger (fetus).
  - Passages (birth canal & maternal pelvis).

HYPOTONIC UTERINE INERTIA

- Protracted latent phase.
- Protracted active phase.
- Prolonged second stage.

Protracted latent phase

- Prolongation of latent phase more than 20 Hour in primipara & 14 hour in multipara.
- The problem is how accurately define the time of onset of labour.
- Management:
  - Assurance.
  - Sedative (prthidine 50 mg)
  - No ecbolic.

Protracted active phase.

- Def:
  - Rate of cervical dilatation less than 1 cm/hour in primipara or less than 1.5 cm/hour in multipara.
- Management:
  - Exclude cephalopelvic disproportion.
  - If problem in contraction ecbolic could be given.

Prolonged 2nd stage

- Prolongation of second stage more than 2 hour in primipara & 1 hour in multipara (plus one hour if epidural analgesia has been given).
- **Causes:**
  - Hypotonic inertia or inefficient bearing down.
  - Malposition.
  - Cephalopelvic disproportion.
  - Epidural analgesia.
  - Rigid perineum.

Prolonged 2nd stage

- **Management:**
  - CS if cephalopelvic disproportion is suspected.
  - Instrumental delivery.

CLASSIFICATION

- **Normal polarity**
  - Hypertonic dysfunction
    - **Precipitate labour:** in the absence of obstruction
    - **Tonic contraction &retraction(bandls ring):** in presence of obstruction.
  - Hypotonic dysfunction (uterine inertia).
- **Abnormal polarity.**
  - **Hypertonic uterine inertia.**
  - Contraction ring.
- **Cervical dystocia.**

HYPERTONIC UTERINE INERTIA

- Increase basal tone.
- Loss of coordinations.
- **Aetiology:**
  - Primipara (elderly primipara).
  - Malposition.
  - Cephalopelvic disproportion.
- **Management:**
  - Sedative.
  - CS if there is maternal or fetal distress.

CLASSIFICATION

- **Normal polarity**
  - Hypertonic dysfunction
    - **Precipitate labour:** in the absence of obstruction
    - **Tonic contraction &retraction(bandls ring):** in presence of obstruction.
  - Hypotonic dysfunction (uterine inertia).
- **Abnormal polarity.**
  - Hypertonic uterine inertia.
  - **Contraction ring.**
- **Cervical dystocia.**

CONTRACTION RING

- It is localized ring of tetanic contraction in the lower part of uterus resulting in hour glass deformation of uterine cavity.
- It usually develop around neck.
- It may lead to arrest of head descend or retained placenta.
- Can be inhibited by general anaesthesia.

Pathological contraction ring

Usually possible to discover during C-section

Pathological Retraction Ring	Constriction Ring
Occurs in prolonged 2nd stage.	Occurs in the 1st, 2nd or 3rd stage.
Always between upper and lower uterine segments.	At any level of the uterus.
Rises up.	Does not change its position.
Felt and seen abdominally.	Felt only vaginally.
The uterus is tonically retracted, tender and the fetal parts cannot be felt.	The uterus is not tonically retracted and the fetal parts can be felt.
Maternal distress and fetal distress or death.	Maternal and fetal distress may not be present.
Relieved only by delivery of the fetus.	May be relieved by anaesthetics or antispasmodics.

CLASSIFICATION

- **Normal polarity**
  - Hypertonic dysfunction
    - **Precipitate labour:** in the absence of obstruction
    - **Tonic contraction &retraction(bandls ring):** in presence of obstruction.
  - Hypotonic dysfunction (uterine inertia).
- **Abnormal polarity.**
  - Hypertonic uterine inertia.
  - Contraction ring.
- **Cervical dystocia.**

CERVICAL RIGIDITY (DYSTOCIA)

- **Types:**
  - 1ry (rare)
  - 2nd (common)
    - Previous operation as amputation, conization cerclage or cauterization… Lead to fibrosis.
- **Complication:**
  - Cervicovaginal fistula.
  - Annular detachment of cervix.


Thank You!