Chest Trauma

khaled M. Abdel-aal

Ass. Prof. & Consultant of Cardiothoracic Surgery

Sohag university

Chest trauma

II. Specific (definite therapy):

Chest trauma

II. Specific (definite therapy):

- Chest wall:
- *Soft tissues (skin, SC, ms).*
- *Boney skeleton :*

  1. ***Ribs*** *Sternum*
  2. *Scapulae*
  3. *Clavicle*

- Pneumothorax
- Hemothorax
- Pulmonary contusion
- Cardiac trauma
- Tracheobronchial injury
- Diaphragmatic trauma
- Trauma to great vessels

Chest trauma

Chest wall:

- ***Soft tissues*** (skin, SC, ms).

1. wound (incised or lacerated).

------- cleaning, debridement, and suturing

2. **Subcutaneous emphysema**

- Air collects in subcutaneous fat from pressure of air in pleural cavity
- Can be seen from neck to groin area
- Need no treatment, just reassurance
- If sever, marked disfigurement -------- multiple small stab incisions.
- ***Significance: it direct attention to the cause and underlying visceral injury.***

Subcutaneous emphysema

Subcutaneous emphysema

Chest trauma

Fracture ribs

- Any disruption of the rib continuity
- Maybe:

  - simple complicated
  - single multiple
- Caused by:

----- direct trauma (sticks, blow), or

-----indirect trauma (anteroposterior compression).

Chest trauma

Fracture ribs

- *Direct trauma:*

1. site of fr, at site of trauma
2. increase incidence of underlying structure injury.

- *Indirect trauma:*

1. Common
2. Site of fr. at the weakest points of the rib
3. Lesser incidence of visceral injury

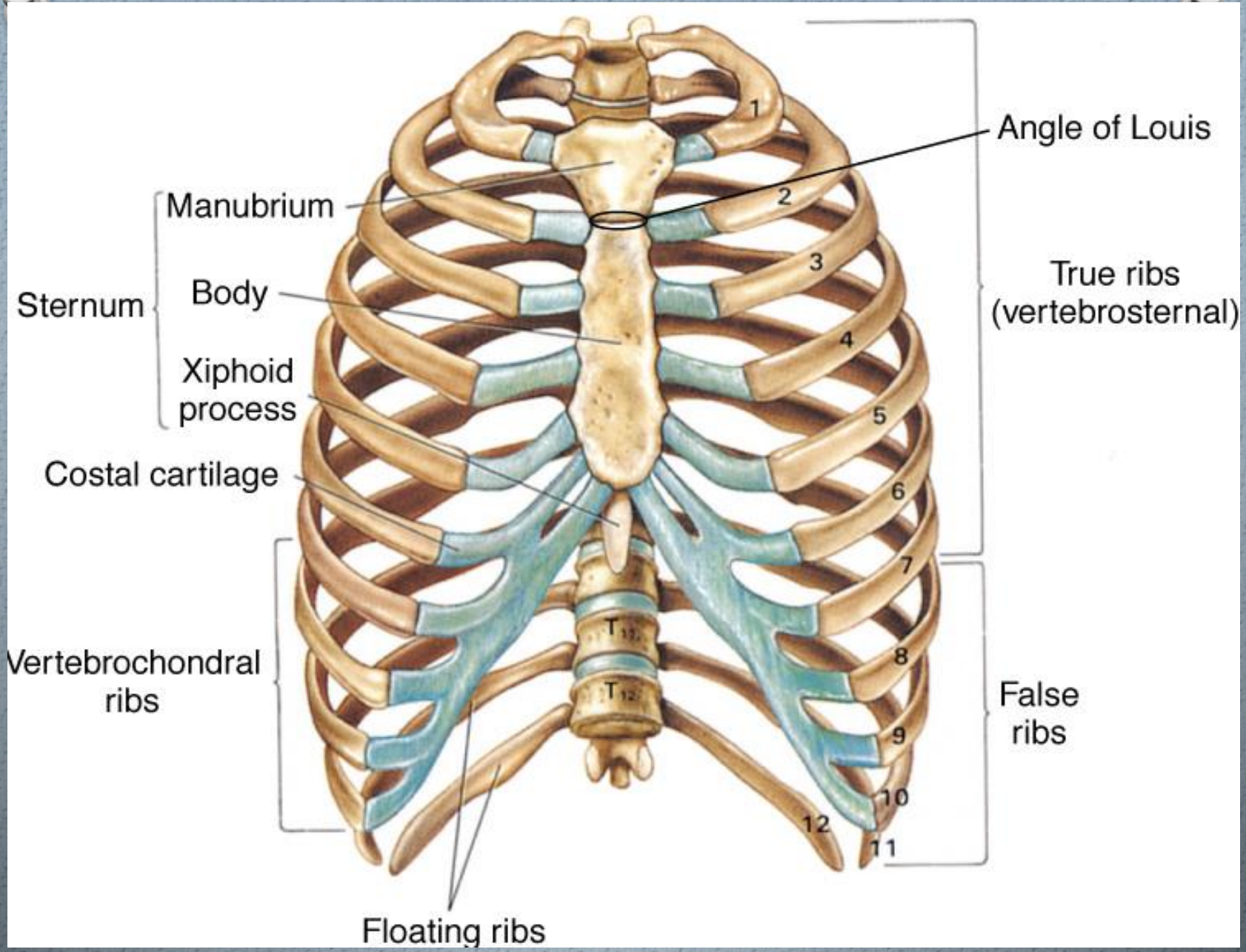
Angle of Louis
Manubrium
Sternum
Body
Xiphoid process
Costal cartilage
True ribs (vertebrosternal)
False ribs
Vertebrochondral ribs
Floating ribs
1
2
3
4
5
6
7
8
9
10
11
12

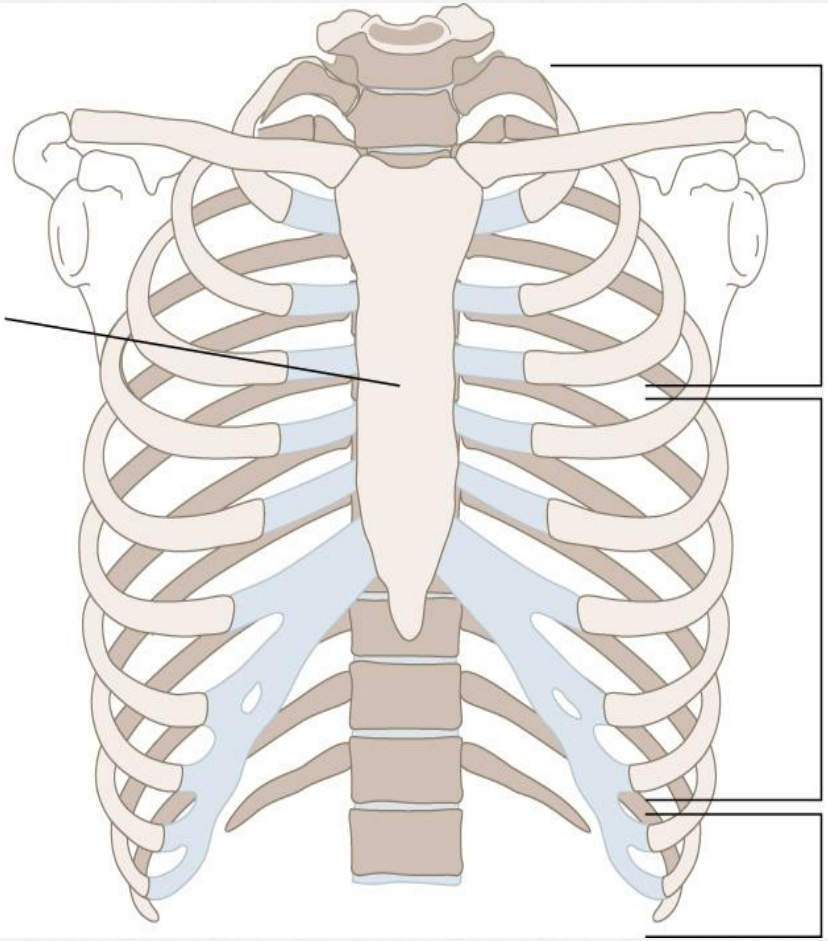
Great force is required for sternal fractures.
Ribs 1–3 are well protected by shoulder bones and muscles.
Ribs 4–9 are most frequently fractured.
Ribs 10–12 are relatively mobile and fracture less frequently.

Chest trauma

Fracture ribs

C/P:

- Sever pain increases by respiratory movement.
- Shallow respiration with decrease resp. movement.
- Sever localized tenderness.
- Maybe boney crepitus.

Diagnosis : C/P, x- ray

Chest trauma

Fracture ribs

Treatment:

1. pain control:

- *Simple analgesics (NSAID)*
- *Pethidine*
- *Intercostal nerve block*
- *Epidural analgesia*

2. Chest strapping (in full inspiration) to decrease pain

3. Chest physiotherapy.

4. Antibiotics, bronchodilators, and expectorants.

Fractured ribs

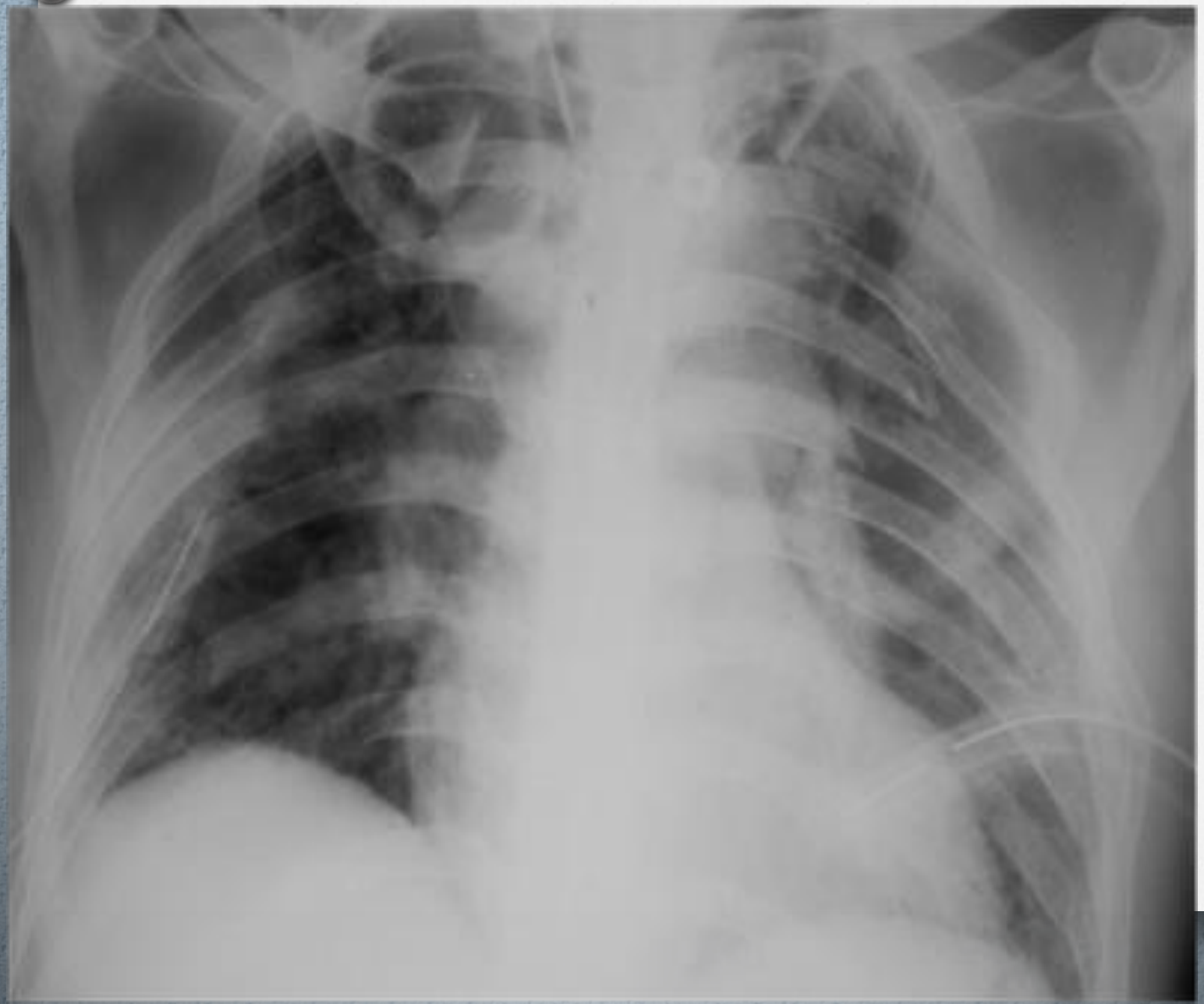

Chest trauma

Multiple fracture ribs

Complicated fracture ribs

(flail segment)(flail chest)

- Segment of chest wall that does not have continuity with rest of thoracic cage.
- Usually 2 fractures per rib in at least 2 ribs.
- Usually severe blunt trauma (motor car, fall from a height)

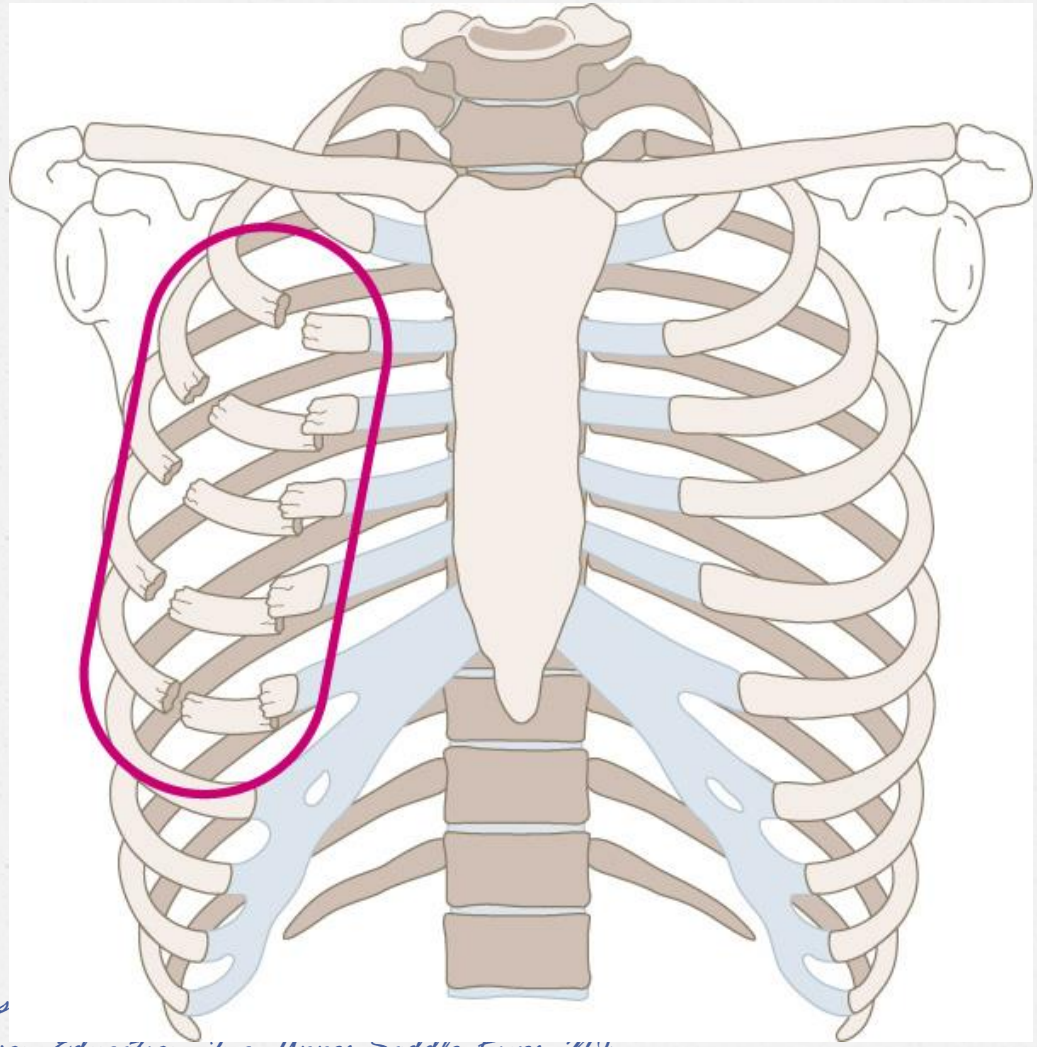

Bledsoe et al., Ess

Flail Chest(multiple fr. Ribs)

- Significant chest trauma
- Mortality rates 20% to 40% due to associated injuries
- Mortality increased with
  - Advanced age
  - Seven or more rib fractures
  - Three or more associated injuries
  - Shock
  - Head injuries

Flail chest

- **Pathophysiology:**
  - Segment does not contribute to lung expansion
  - Disrupts normal pulmonary mechanics
  - Accompanied by pulmonary contusion in 50% of patients
- **Paradoxical respiration**
- **Pendulum respiration**
- **Mediastinum flutter**

Flail chest (Multiple Rib Fractures)

Pathophysiology:

- Atelectasis
- Hypoventilation
- Inadequate cough
- Pneumonia

Falail chest

Diagnosis:

- Paradoxical chest wall movement
- Sever pain
- Dyspnea, tachypnea, irritability
- May be cyanosis, shock
- Hypoxia
- X-ray (fr. Ribs, pneumothorax, hemothorax etc)

Treatment of Flail Chest

Aim:

- Management is directed towards protecting the underlying lung and allowing adequate oxygenation, ventilation and pulmonary toilet.
- This strategy is aimed at preventing the development of pneumonia, which is the most common complication of chest wall injury.

Flail chest **Therapy**

1. **Pain control (analgesia):**

- Analgesia is the mainstay of therapy for rib fractures.
- Allows normal free inspiration and coughing.
- NSAIDS
- Opioids: morphia, pethidine,

PCA (patient controlled administration of opioid infusion)

- (intercostal nerve block)
- **Epidural analgesia**

Falail chest

Therapy

2. Chest physiotherapy.

3. antibiotics, expectorants, and bronchodilators.

(pulmonary toilet or hygiene)

4. Intubation & Ventilation:

- ✓ Rarely indicated
- ✓ usually for hypoxia due to underlying pulmonary contusions
- ✓ When there is sever chest wall instability (internal pneumatic stabilization)

Flail chest

Therapy

Intubation & Ventilation:

- ✓ usually necessary only until the resolution of the pulmonary contusion.
- ✓ Healing and stabilization of rib fractures is rarely the limiting step in weaning from mechanical ventilation.

Flail chest

Therapy

5. Chest tube insertion: ICT

For pneumothorax, hemothorax, or hemopneumothorax

N.B: NO prophylactic ICT

6. Rib fracture fixation:

- Has been fluctuated over the last 50 years.
- External fixation and stabilisation was common for large chest wall injuries prior to the development of tracheal intubation and mechanical ventilation.

Flail chest Therapy

6. Rib fracture fixation:

- Positive pressure ventilation essentially provides an 'internal stabilisation' to the thoracic cage as well as improving oxygenation and ventilation for the management of pulmonary contusion.
- Hence it has essentially replaced fracture fixation over the past twenty years.
- In the last few years however a few studies have suggested that some groups of patients may benefit from early fracture fixation.

allowing earlier weaning from mechanical ventilation and reducing acute complications and chronic chest wall pain.

Flail chest (multiple fr. Ribs)

N.B:

Splinting (strapping):

- Not circumferential
- May leads to decrease chest wall movement, atelectasis and ventilation-perfusion mismatch (ventilated alveoli that are not perfused or perfused alveoli that are not ventilated)

Bulky Dressing for splint of Flail Chest

- Use Trauma bandage and Triangular Bandages to splint ribs.

Sternal Fracture & Dislocation

- Associated with severe blunt anterior trauma
- Mortality: 25-45%
  - Myocardial contusion
  - Pericardial tamponade
  - Cardiac rupture
  - Pulmonary contusion
- **Treatment:**

1. conservative: bed rest – strapping – pain
2. surgical: in displaced fr. (thoracotomy & internal fixation with wires)

Chest trauma Pneumothorax

Definition:

Air in the pleural cavity

Types:

------ Closed (simple) pneumothorax

------ open peumothorax

------ tension pneumothorax

Closed (simple) pneumothorax

- Air in the pleural space due to alveolar (pulmonary) injury or rupture
- Incidence
  - 10% to 30% in blunt chest trauma
  - Almost 100% with penetrating chest trauma
- Morbidity/mortality
  - Extent of atelectasis (lung cpllapse)
  - Associated injuries
  - A common cause of pneumothorax is a fractured rib that penetrates the underlying lung.

Closed (Simple) Pneumothorax

- May occur in the absence of rib fractures from:

  A sudden increase in intrathoracic pressure generated when the chest wall is compressed against a closed glottis

- Small tears self-seal; larger ones may progress.

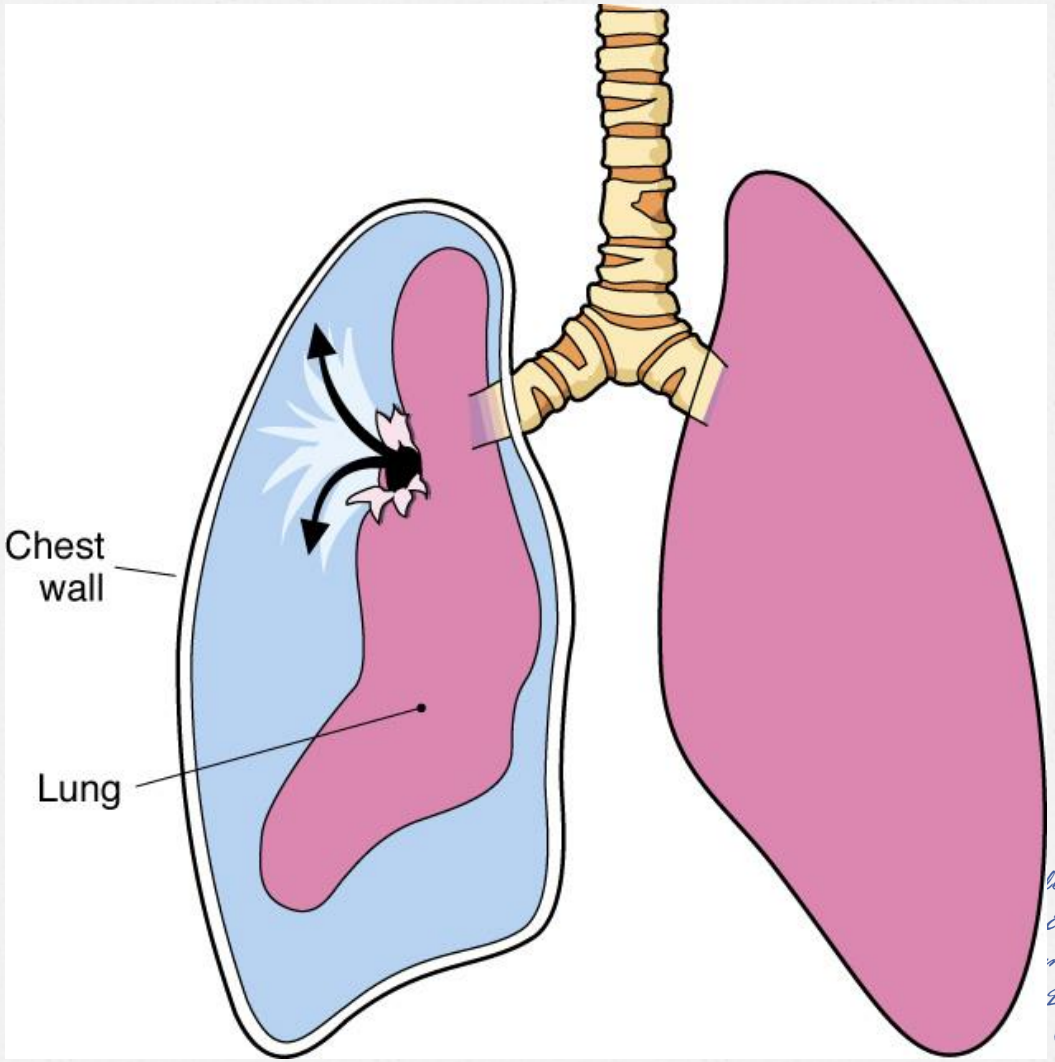

Bledsoe et al., Essentials of Emergency Care: Division III © 2006 by Pearson Education, Inc. Upper Saddle River, NJ

Closed Pneumothorax

- **Clinical Findings:**
  - Tachypnea Tachycardia
  - Respiratory distress
  - Absent or decreased breath sounds on the affected side
  - Hyperresonance
  - Decreased chest wall movement
  - Slight pleuritic chest pain
- **Diagnosis:** C/P, chest x- ray

Closed Pneumothorax

- **Management**:

1. ABC
2. Conservative treatment (if <20% collapse)

With follow up chest x-ray

2. Tube thoracostomy (follow up x-ray)

Open pneumothorax

- Opening in chest cavity and/or the lung that allows air to enter pleural cavity freely with each respiration
- Causes the lung to collapse due to increased pressure in pleural cavity
- Can be life threatening and can deteriorate rapidly
- Usually the result of penetrating trauma

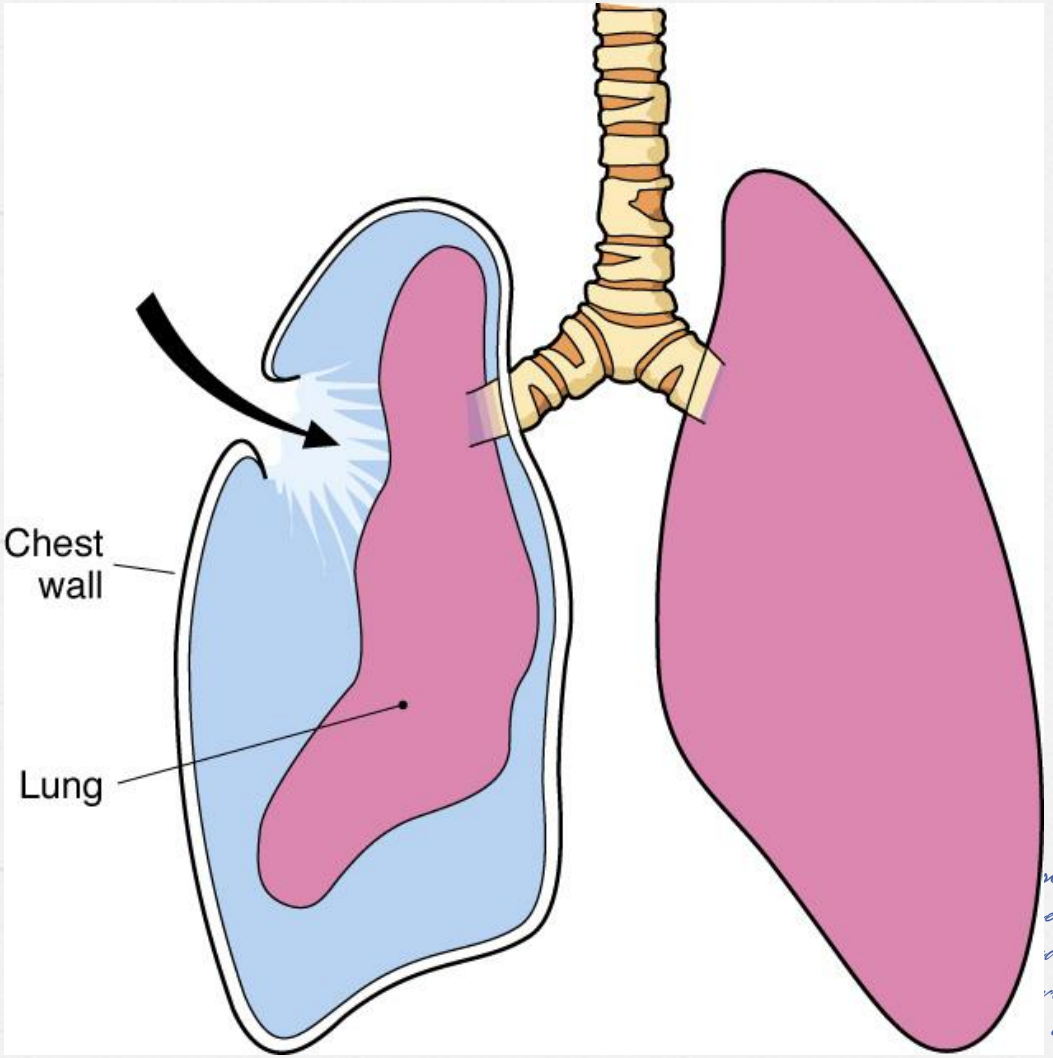

Open Pneumothorax

Pathophysiology:

- An open defect in the chest wall (>3 cm)
  - If the chest wound opening is greater than two-thirds the diameter of the trachea, air follows the path of least resistance through the chest wall with each inspiration.
  - As the air accumulates in the pleural space, the lung on the injured side collapses and begins to shift toward the uninjured side.

Open Pneumothorax

- **Pathophysiology:**
  - Very little air enters the tracheobronchial tree to be exchanged with intrapulmonary air on the affected side, which results in decreased alveolar ventilation and decreased perfusion.
  - The normal side also is adversely affected because expired air may enter the lung on the collapsed side, only to be rebreathed into the functioning lung with the next ventilation.
- *May result in severe ventilatory dysfunction, hypoxemia, and death unless rapidly recognized and corrected.*

Open Pneumothorax

- **Clinical picture:**
- A defect in the chest wall
- A penetrating injury to the chest that does not seal itself
- A sucking sound on inhalation
- Tachycardia
- Tachypnea
- Respiratory distress
- Subcutaneous emphysema
- Decreased breath sounds on the affected side

Open Pneumothorax

Management:

- Airway and ventilation management.

  High concentration oxygen

  Positive-pressure ventilation if necessary.
- Occlude the open wound—apply an occlusive sterile gauze dressing .
- Tube thoracostomy

Tension Pneumothorax

- Can occur with:
  - A penetrating injury to the chest
  - Blunt trauma
  - Penetration by a rib fracture
  - Many other mechanisms of injury
- Profound hypoventilation can result.
- Death is related to delayed management.
- ***An immediate, life-threatening chest injury.***

Tension Pneumothorax

Pathophysiology:

- Occurs when air enters the pleural space from a lung injury or through the chest wall without a means of exit.
- When air is allowed to leak into the pleural space during inspiration and becomes trapped during exhalation, an increase in the pleural pressure results.
- Increased pleural pressure produces mediastinal shift.

Tension Pneumothorax

Clinical picture:

- Extreme anxiety
- Cyanosis
- Increasing dyspnea
- Tachycardia
- Diminished or absent breath sounds on the injured side
- Tachypnea
- Respiratory distress
- Tracheal deviation (a late sign)

Tension Pneumothorax Physical Findings

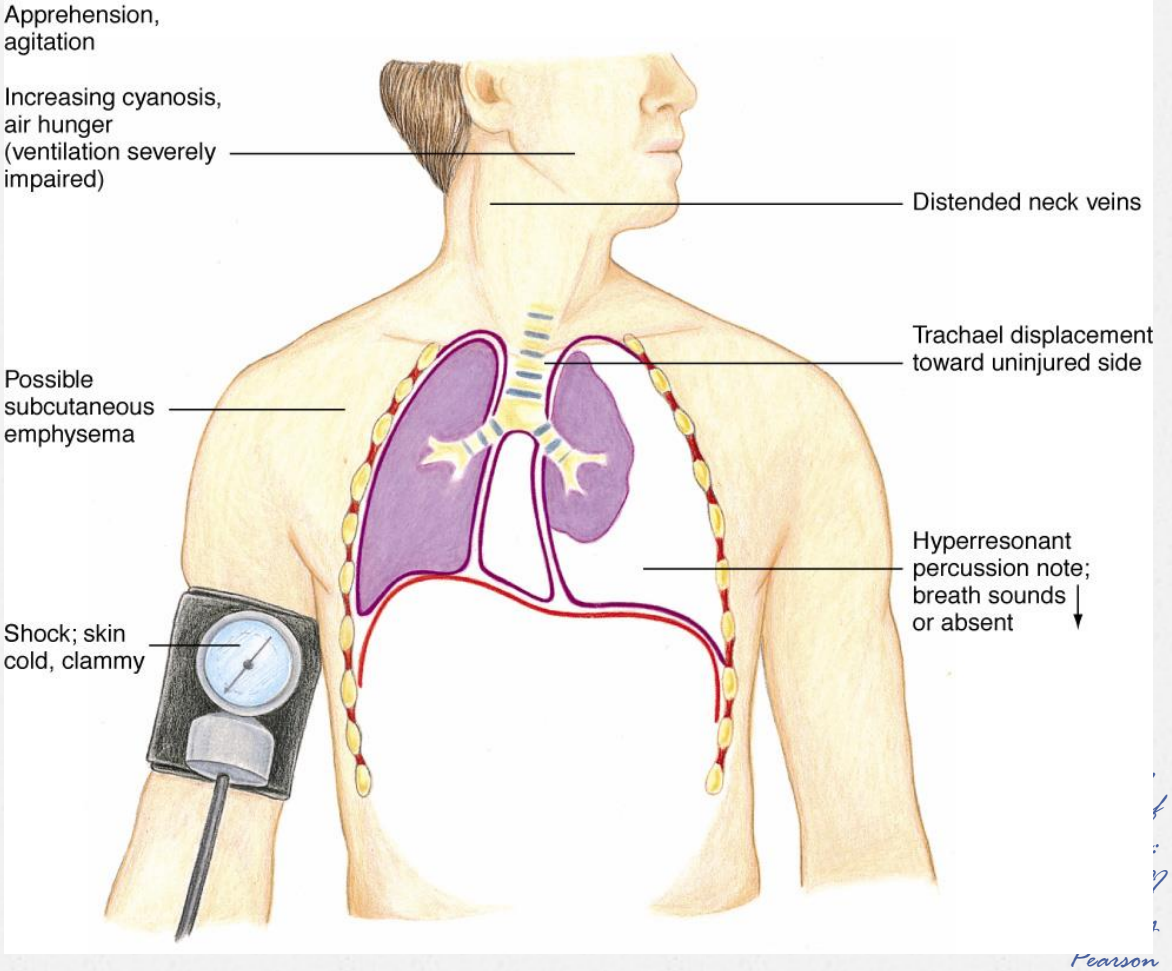

Tension Pneumothorax

Management :

- Emergency care is directed at reducing the pressure in the pleural space.
  - Occlude open wound
  - Needle thoracostomy
  - Tube thoracostomy—in-hospital management

Hemothorax

- **Definition.**
- **Degrees :** (according to the amount)
  - Mild: 350 ml
  - Moderate: < 1500 ml
  - Severe (massive): >1500 ml
- **Aetiology:**

1. **Traumatic**
2. Following chest operations
3. Spontaneous : tumours

Hemothorax

Source (origin):

1. Systemic (75- 80%)
2. Pulmonary (10- 15%)
3. Fatal (about 5%)

Fate (pathology):

Hemothorax never absorb or coagulated spontaneously due to continuous movement of the chest, lungs and diaphragm. If untreated it undergoes:

Hemothorax

- **Fate (pathology):**

If untreated it undergoes:

1. Defibrination : due to lung movement , so remain unclotted
2. Clotting: irritation of the pleural surfaces by blood lead to protien rich effusion-------- clotting & fibrin deposition on the pleural surfaces.
3. Organization: fibrin to fibrin tissue which interfere with chest and lung movement (frozen chest)
4. Infection: -------empyema

Hemothorax

Clinical picture:

a). Picture of internal bleeding:

- Hypotension, Narrowed pulse pressure
- Pale, cool, moist skin, shock

b). Picture of pleural effusion:

- Hyporesonance (dullness on percussion) on the affected side
- Tracheal deviation to the unaffected side (rare)
- Tachypnea, Dyspnea, Cyanosis
- Diminished or decreased breath sounds on the affected side

Hemothorax

Management:

- Airway and ventilation
- Administer volume-expanding fluids to correct hypovolemia (blood is better)
- tube thoracostomy
- Thoracotomy:

1. Massive
2. Continuous
3. Clotted
4. Organized
5. infected

Diaphragmatic Rupture
traumatic diaphragmatic hernia

- A tear in the Diaphragm that allows the abdominal organs enter the chest cavity
- More common on Left side (90%) due to liver helps protect the right side of diaphragm
- Associated with multipile injury patients
- Common and usually missed especially in penetrating injuries

Diaphragmatic Rupture
traumatic diaphragmatic hernia

- **Aetiology:**

1. Open wound: stab and bullet
2. Closed injury: blunt trauma

- **Clinical picture:**

1. History of trauma
2. Abdominal Pain
3. Shortness of breath
4. Inspection: decrease resp. movement
5. Percussion: dullness with areas od hyperesonance due to
6. Auscultation: decrease air entery—intestinal sounds may be heard

Diaphragm Rupture

Diaphragmatic Rupture

- **Management:**

Suturing of the diaphragmatic injuries by non absorpable or delayed absorpable sutures(?), with interrupted (?), in 2 layers.

a). Early diaphragmatic H.:

LAPAROTOMTY (why)

b). Late D.H. :

THORACOTOMY (why)

Cardiac trauma

- Cardiac tamponade
- Post traumatic VSD
- Post traumatic MR
- Post traumatic coronary insufficiency
- Traumatic cardiac contusion

Thank you