Fractures of the Humeral Shaft

Abdelrahman Hafez Khalifa, MD

Sohag University Hospital
Orthopaedic Department

Introduction

- Humeral fractures traditionally treated nonsurgically, with predictably satisfactory outcomes.
- Strong bias formerly existed against surgical intervention due to high rate of complications.
- Both operative and nonoperative treatments have been refined.

Relevant Anatomy

- Humeral diaphysis extends from the upper border of the insertion of the pectoralis major proximally to the supracondylar ridge distally

- Fracture alignment determined by the location of the fracture relative to the major muscle attachments, most notably the pectoralis major and deltoid attachments

Deforming Forces

- Example of a fracture distal to pectoralis major attachment and proximal to deltoid tuberosity
- Adduction of proximal fragment results

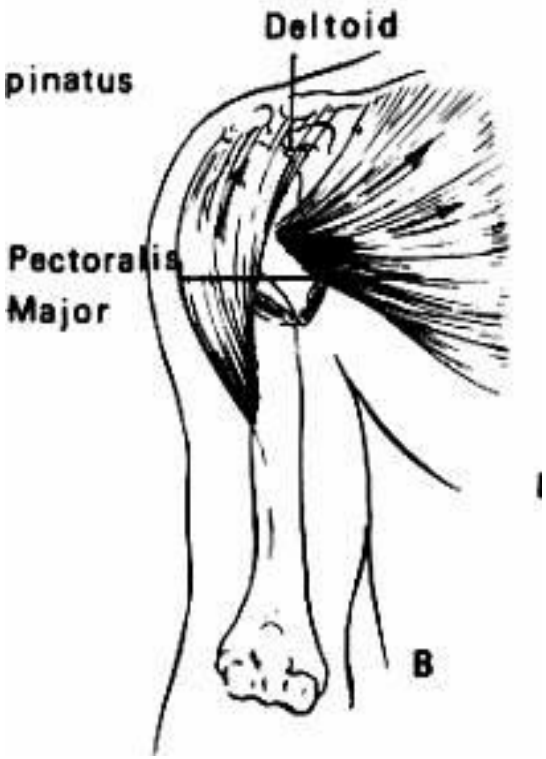

Reproduced with permission from Epps H Jr., Grant RE: "Fractures of the shaft of the humerus" in Rockwood CA Jr., Green DP, Bucholz RW (Eds.) *Rockwood and Green's Fractures in Adults* Ed 3, Philadelphia, PA JB Lippincott, 1991, Vol. 1, pp: 843-869

- Example of a fracture distal to deltoid tuberosity
- The proximal fragment is abducted and shortening occurs at fracture site due to pull of biceps and triceps

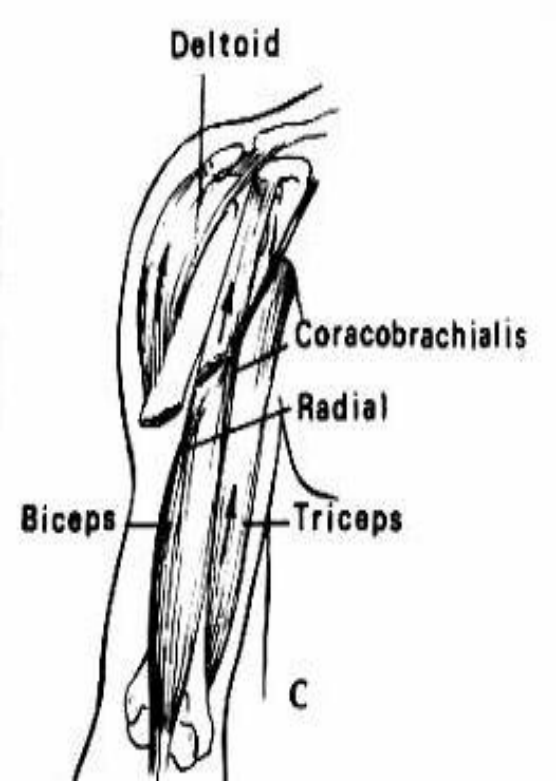

Reproduced with permission from Epps H Jr., Grant RE: "Fractures of the shaft of the humerus" in Rockwood CA Jr., Green DP, Bucholz RW (Eds.) *Rockwood and Green's Fractures in Adults* Ed 3, Philadelphia, PA JB Lippincott, 1991, Vol.. 1, pp. 843-869

Classification Systems

- Classification based on fracture descriptors
- AO Classification

Fracture Descriptors

- Location
- Pattern
- Low-energy vs. high-energy
- Open / Closed Injury Classifications

AO Classification

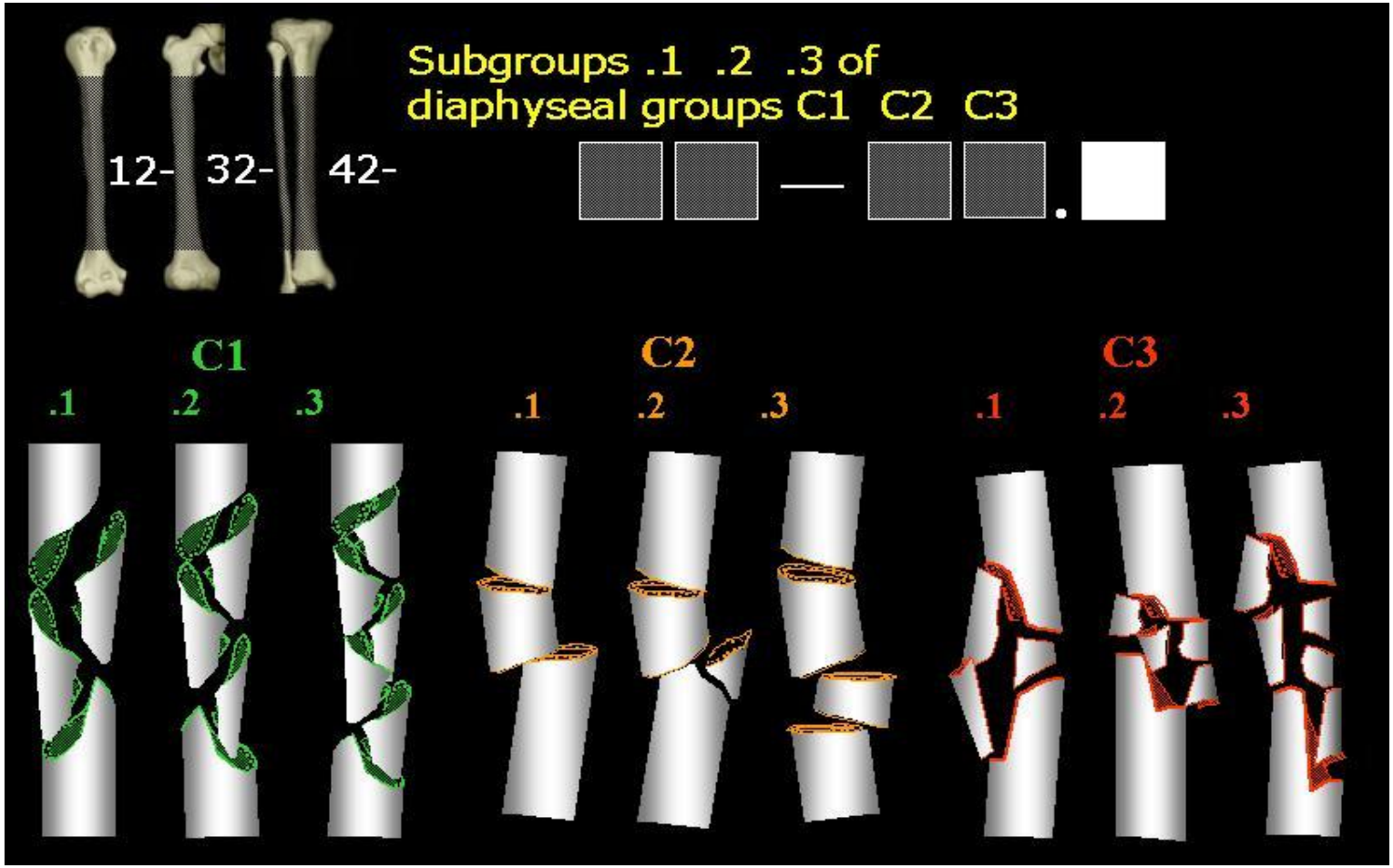

Mechanism of Injury

- Direct or indirect forces
- Violent muscle contraction

Physical Examination

- Cardinal signs of long bone fracture include:
  - pain
  - swelling
  - deformity
- Look for associated injuries
- Document neurovascular exam!
- Radial Nerve Function

Imaging

- Standard radiographic examination
  - AP
  - lateral view
  - Both joints
- CT/MRI if pathologic fx suspected, xrays not clear

Nonsurgical Treatment

- Most humeral fractures are amenable to closed, nonsurgical treatment
  - rigid immobilization is not necessary for healing
  - perfect alignment is not essential for an acceptable result

Nonsurgical Treatment - Requirements

- An understanding by the treating physician of the postural and muscular forces that must be controlled
- A dedication to close patient supervision and follow-up
- A cooperative and preferably upright and mobile patient
- An acceptable reduction

What is Acceptable Alignment?

- Because the shoulder and elbow are joints capable of wide ranges of motion, the arm is thought to be able to accommodate the following without a significant compromise of function or appearance:
  - 20 degrees of anterior or posterior angulation
  - 30 degrees of varus (less in thin patients)
  - 3 cm of shortening

Closed Treatment

- Initial immobilization with either a U shaped slab coaptation splint or a hanging arm cast with conversion to a functional brace in the subacute phase when swelling and pain have improved.
- Coaptation splint is preferred due to the support it offers proximal to the fracture site

Functional Bracing for the Humerus

- Principles were introduced by Sarmiento in 1977
  - 98% union rate with good functional restoration and minimal angular deformity
  - Nearly full ROM of the extremity were restored and complications were minimal

Functional Bracing for the Humerus

- Effects fracture reduction through soft-tissue compression
- Consists of an anterior and posterior shell held together with Velcro straps
- Can be applied acutely or following application of a coaptation splint
- Success depends on:
  - Upright patient
  - Tightening daily
  - Cannot lean on elbow

Contraindications to Functional Bracing

- Massive soft-tissue or bone loss
- An unreliable or uncooperative patient
- An inability to obtain or maintain acceptable fracture alignment
- Fracture gap present - increases risk of nonunion

Surgical Treatment

- Surgical intervention is preferable in specific cases
  - Injury Related Factors
  - Patient Related Factors

Indications for ORIF - Injury Factors

- Failed closed treatment
  - Loss of reduction
  - Poor patient tolerance/compliance
- Open fractures
- Vascular injury/neurologic injury
- Floating elbow

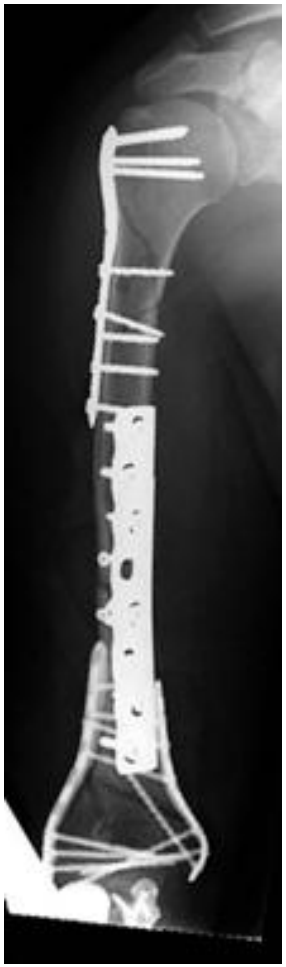

Indications for ORIF - Injury Factors

- Associated intra-articular fractures
- Associated injuries to the brachial plexus
- Chronic problems
  - Delayed union
  - Nonunion/malunion
  - Infection
- Only open fractures and those with vascular injury present absolute indications for surgical intervention

Indications for ORIF - Patient Factors

- Polytrauma-requiring arm for mobilization
  - Head injuries
  - Burns
  - Chest trauma
  - Multiple fractures
- Patient unable to be upright
- Bilateral fractures of the humerus
- Pathologic fractures

Surgical Treatment

- If surgical intervention is elected, the following options are available:
  - Plate osteosynthesis
  - Intramedullary fixation
  - External fixation
- There is no role for stabilization of the humeral shaft by screw fixation alone due to the high bending and torsional forces imposed on the humerus during patient and extremity mobilization

Plate Osteosynthesis

- The best functional results after surgical management of humeral shaft fractures have been reported with the use of plates and screws
- These implant allow direct fracture reduction and stable fixation of the humeral shaft without violation of the rotator cuff

Plate Osteosynthesis

- **Results:**
  - Union rates averaged 96% with significant complications ranging from 3% to 13%
  - motion restrictions at the elbow or shoulder usually due to other severe bony or soft-tissue injuries to the same extremity

Plate Osteosynthesis-Approaches

- The surgical approach is dependent on the fracture level and the need to visualize the radial nerve
- Anterolateral , posterior, and lateral approaches are supported by the literature
- The anterolateral approach is preferred for proximal third fractures
- The anterolateral and posterior approach are both adequate for midshaft and distal third fractures
- Lateral approach gives good exposure of entire shaft, but is less familiar.

Anterolateral Approach

- Benefits of anterolateral approach
  - Supine positioning
  - Proximal extension possible via deltopectoral interval

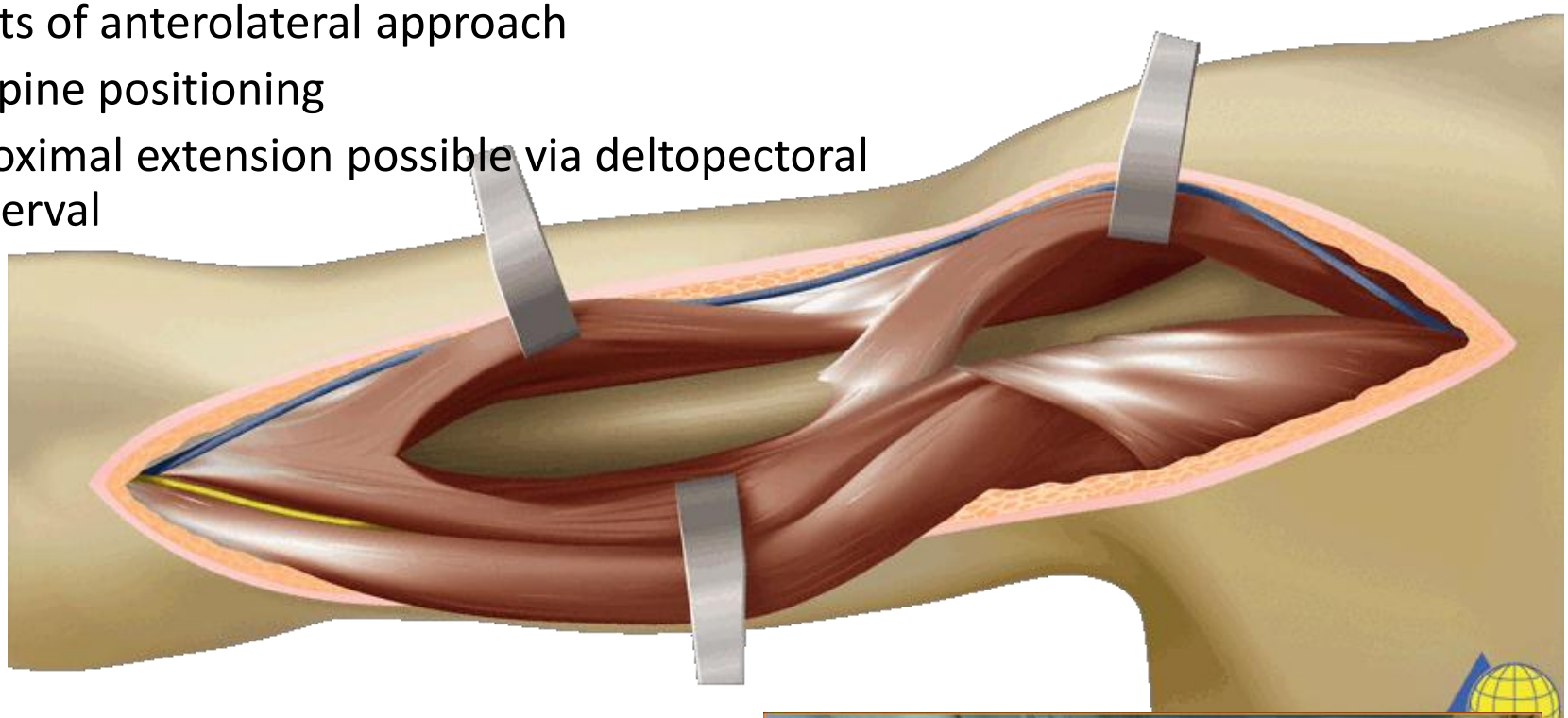

- Drawbacks of anterolateral approach
  - Allows for less direct exposure of radial nerve since it lies posterior to intermuscular septum
  - Difficulty in applying plate to lateral aspect of humerus for distal fractures

Posterior Approach

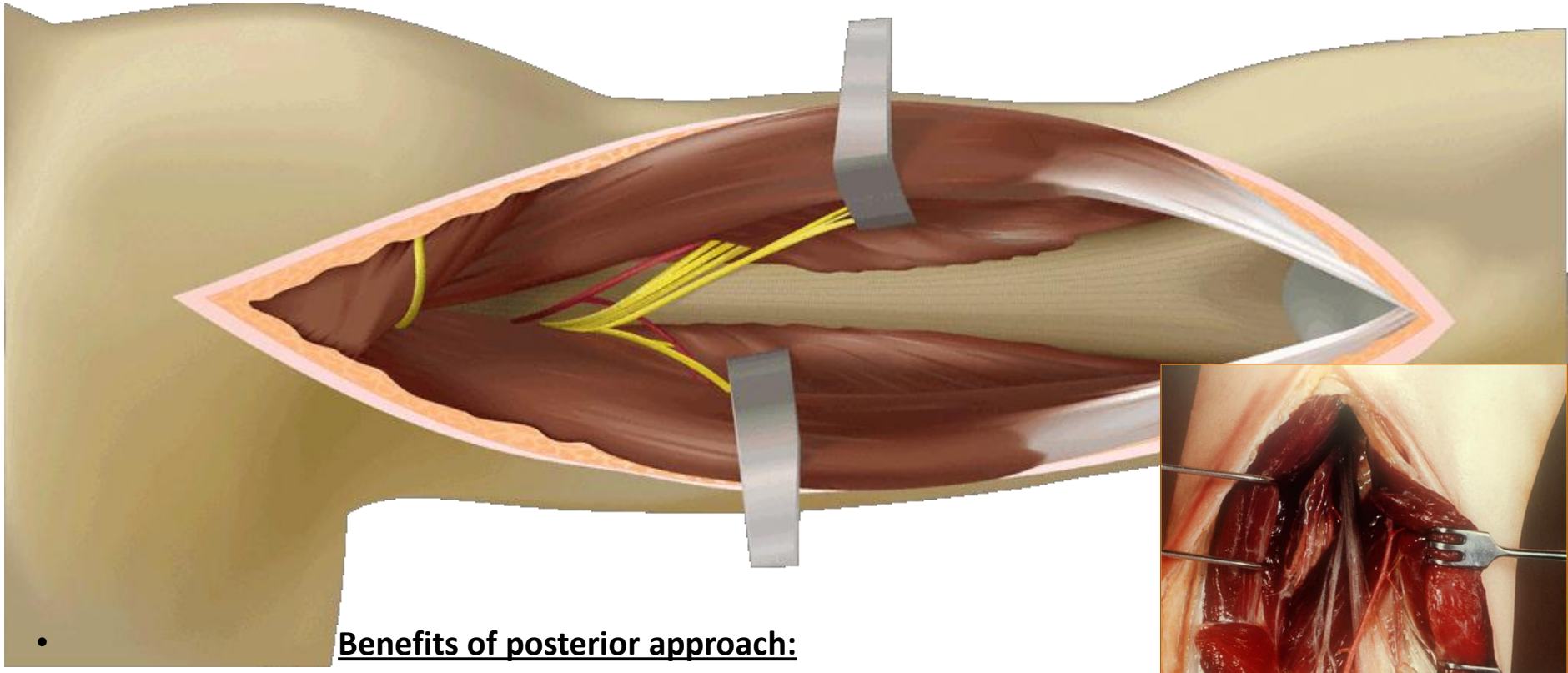

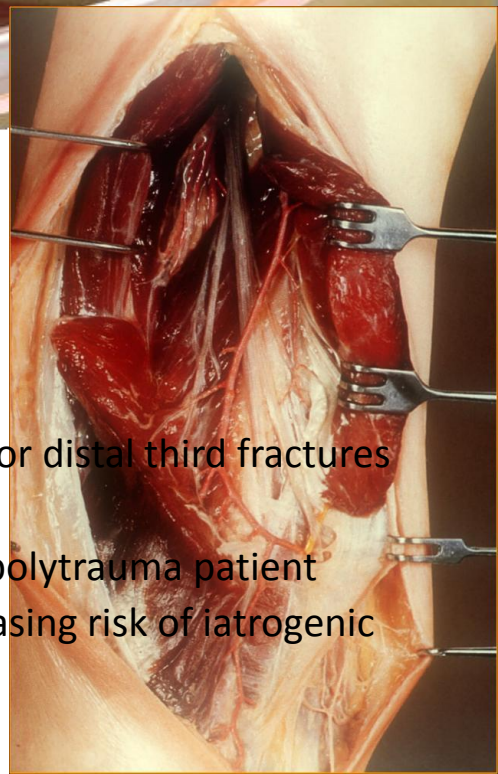

- **Benefits of posterior approach:**
  - Allows more direct exposure of the radial nerve
  - Allows application of a broad plate to flat surface of distal humerus for distal third fractures
- **Drawbacks to posterior approach:**
  - Requires lateral or prone positioning which may be problematic for polytrauma patient
  - Requires nerve mobilization for plate application, theoretically increasing risk of iatrogenic palsy

Lateral Approach

- **Benefits of posterior approach:**
  - Allows direct exposure of the radial nerve
  - Extensile
  - Supine position
- **Drawbacks to posterior approach:**
  - Less familiar to surgeons
  - Posterior antebrachial cutaneous nerve at risk

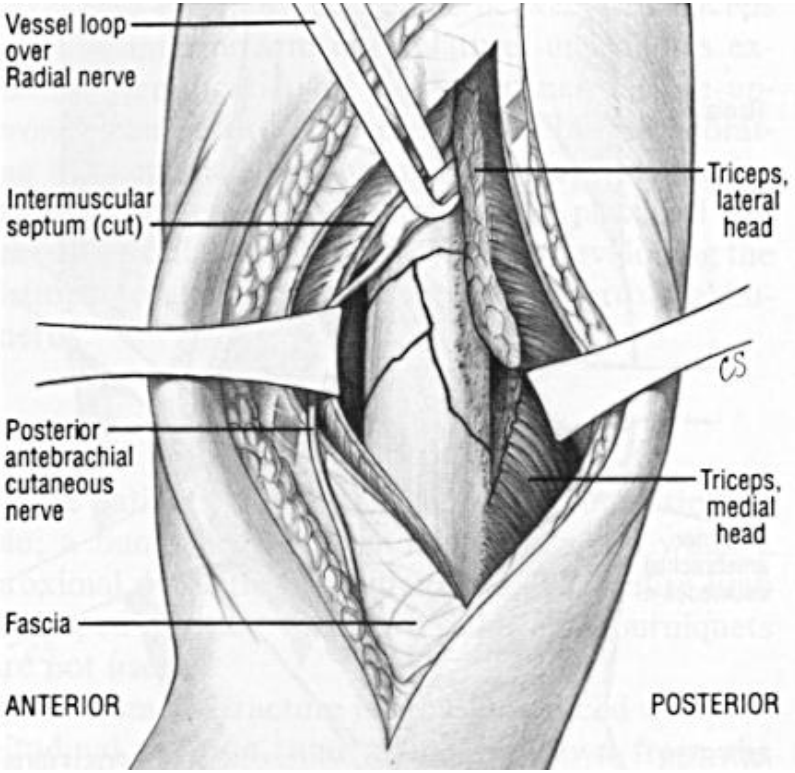

Mills WJ, Hanel DP, Smith DG, J Orthopedic Trauma 10: 81-6, 1996.

Technique & Choice of Implant

- During fracture exposure, excessive soft-tissue stripping must be avoided
- Take care to preserve soft-tissue attachments, and vascularity to butterfly fragments
- Remember sound plating techniques
  - Pre bend plate for transverse fracture

Plate Osteosynthesis: Choice of Implant

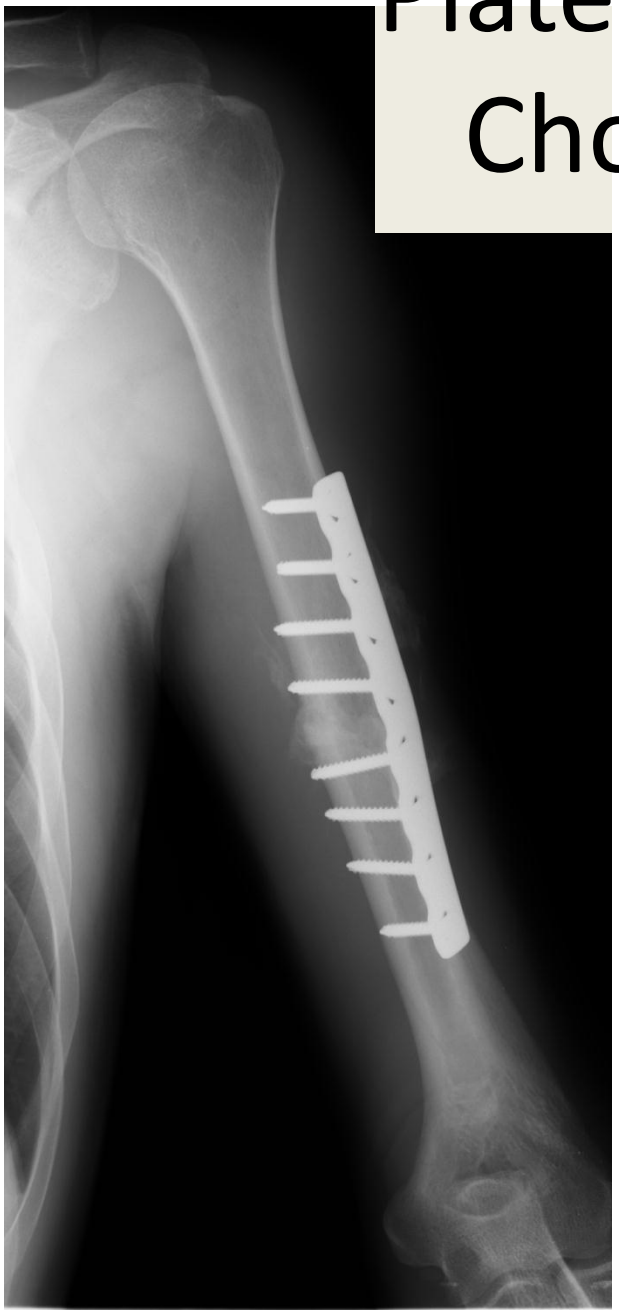

- Humeral shaft is subject to large rotational forces
- Broad 4.5-mm compression plate with staggered holes was developed specifically for use in tubular bones subject to these forces
- Theoretically, the in-line nature of the holes in the narrow 4.5-mm plate increases the chance of a longitudinal stress fracture when a rotational force is applied

Plate Osteosynthesis: Choice of Implant

- The anterolateral application of a plate for proximal and middle 1/3 shaft fractures is relatively straightforward
- Placement of a broad plate anteriorly on the narrow lateral condyle for distal 1/3 shaft fractures is technically difficult
- When fracture is in the distal 1/2 of the humeral shaft, a posterior approach for placement of a plate on the flat surface of the posterior humerus is often accomplished more easily

Plate Osteosynthesis: Choice of Implant

- The narrow 4.5-mm DCP, limited contact plates, and even 3.5-mm DCP may be acceptable implants with proper attention to the details of reduction and stabilization
- Narrow 4.5 mm DCP plates will allow immediate weight bearing for crutch/walker use.

Plate Osteosynthesis

- Injury film of patient with bilateral humeral shaft fractures and C5-C6 fracture-dislocation
- Surgical intervention is indicated

Plate Osteosynthesis

- ORIF performed through anterolateral approach
- Lag screw placed though plate
- 4 bicortical screws placed in each fracture fragment
- Uneventful union followed

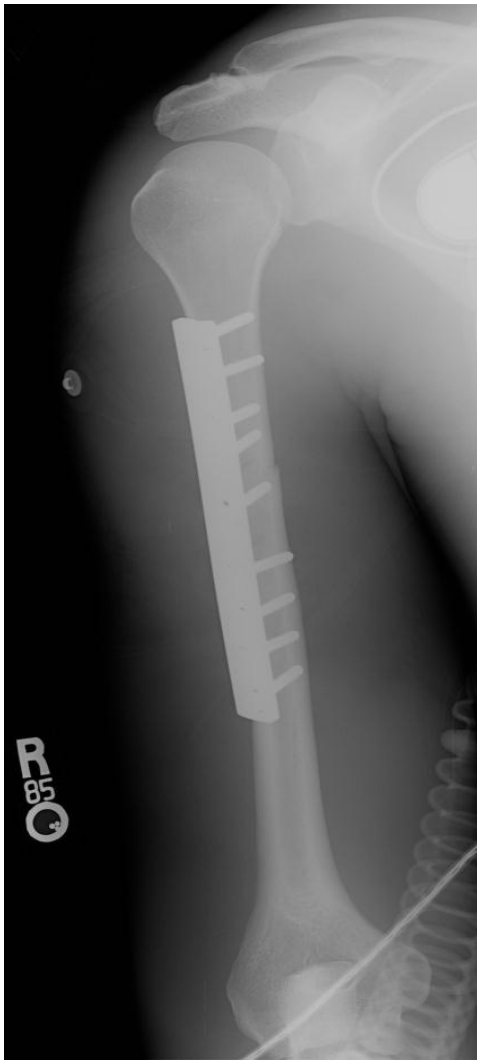

Intramedullary Fixation

- IMN (Intramedullary Nails) offers biologic and mechanical advantages over plates and screws
- IMN can be inserted without direct fracture exposure, minimizing soft-tissue scarring
- Because the implant is closer to the mechanical axis than a plate, they are subject to smaller bending loads than plates and are less likely to fail by fatigue

Intramedullary Nailing

- IMN can act as load-sharing devices in fractures that have cortical contact if the nail is not statically locked
- Stress shielding, with cortical osteopenia, commonly seen with plates and screws, is minimized with intramedullary implants

Intramedullary Nailing-Indications

- Segmental fractures for which plate placement would require considerable soft-tissue dissection
- Humerus fractures in osteopenic bone
- Pathologic humeral fractures
- Highly comminuted fractures, shaft fractures with extension to surgical neck

Intramedullary Nails

- Two types of IMN are available for use in the humeral shaft:
  - Flexible Nails
  - Interlocked Nails

Flexible Nailing

- Retrograde insertion of 3.0 mm elastic Titanium nails allowed healing of this segmental humerus fracture with callus

Flexible Nailing

- Retrograde Enders nailing of this displaced humeral shaft fracture in a polytrauma patient allowed healing to occur with exuberant callus

Flexible Nails-Outcomes

- Early reports of using antegrade insertion method documented unacceptable rates of nonunion, delayed union, and postoperative shoulder pain
- Series in which retrograde insertion method was used have shown better outcomes
  - Alignment was consistently good
  - No association with loss of elbow ROM

Interlocked Nails

- In the past, these nails required reaming of the canal to accommodate their larger size
- Concerns about damage to the radial nerve during reaming have led to the development of implants small enough to be inserted without prior reaming
- Beware of “Jamming” nail into tight distal segment, causing fracture distraction.
- Many of these nails are solid

Flexible Nails

- Many types: Hackenthal nails, Rush rods, and 3.5-mm Enders nails
- Rationale: fill the canal with multiple nails and to achieve an interference fit, creating both rotational and bending stability
- Relatively poor stability
- Use should be reserved for humeral shaft fractures with minimal comminution

Interlocked Nails: Proximal Locking

- Typically done with outrigger attached to nail
- Screws inserted from lateral to medial, or obliquely
- Screws protruding beyond the medial cortex may potentially impinge upon the axillary nerve during internal rotation
- Anterior to posterior screws are avoided due to potential for injury to the main trunk of the axillary nerve

Interlocked Nails: Distal Locking

- Usually consists of a single screw in the anteroposterior plane
- Distal locking screw can be inserted anterior to posterior or posterior to anterior via an open technique, minimizing the chance of neurovascular injury
- Lateral - medial screws risk injury to lateral antebrachial cutaneous nerve

Interlocked Nails: Insertion Techniques

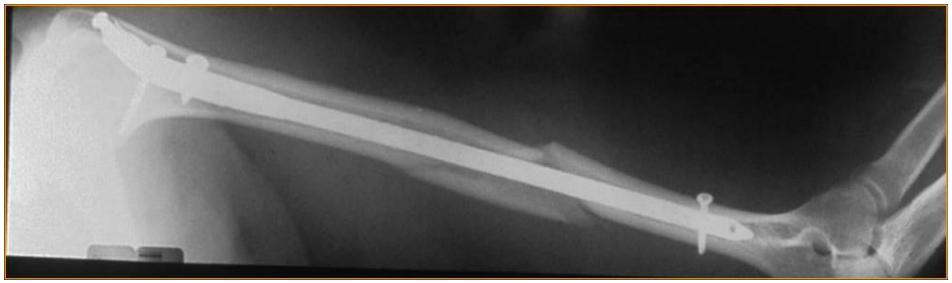

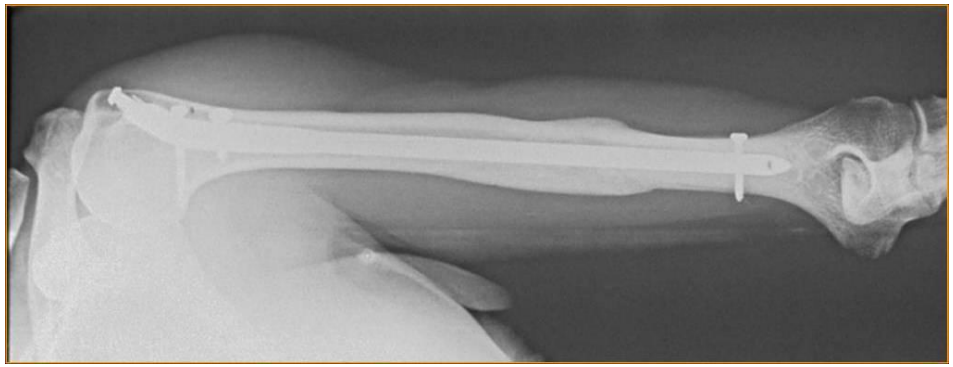

- Antegrade insertion involves opening the IM canal proximally in the vicinity of the rotator cuff
- The optimal location and the proximal method of entry remain controversial
- Nail must be seated beneath the cuff to prevent impingement
- High incidence of shoulder pain plagues technique of antegrade insertion of humeral nails

Interlocked Nails: Insertion Techniques

- Retrograde insertion involves opening the IM canal at a point proximal to the olecranon fossa
  - Supracondylar portal weakens humerus considerably in torsion (Strothman, JOT 14:101, 2000)
- Care must be taken to prevent creation of an iatrogenic distal humerus fracture
- No significant problems with postoperative elbow ROM

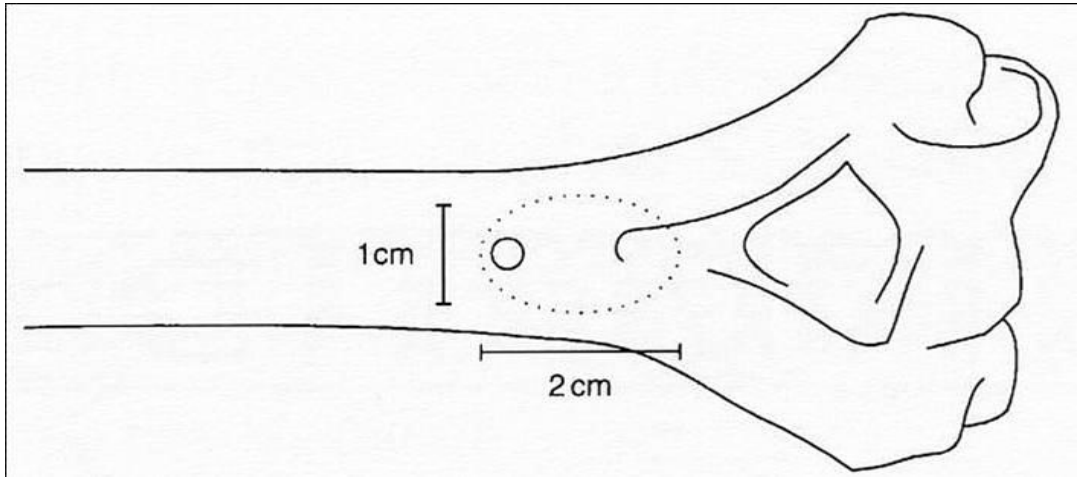

Interlocked Nails: Reaming

- Reaming increases the length along which the nail contacts the endosteal surface, thereby providing better fracture stability
- Reaming decreases the risk of nail incarceration
- Reaming decreases the risk of fracture diastasis
- Reaming permits placement of a larger diameter, and therefore stronger nail
- Reaming produces potentially osteogenic morselized bone chips, which may enhance fracture healing

Interlocked Nails: Reaming

- Reaming obliterates the nutrient artery and endosteal blood supply
- Blood supply will reconstitute if the nail has channels along its length
- Since the cortical thickness of the humerus is much less than that of the femur and tibia, excessive endosteal reaming may thin the humeral cortex and result in increased fracture comminution

Interlocked Nailing

- Closed locked nailing of this pathologic humeral shaft fracture secondary to multiple myeloma resulted in pain relief

Interlocked Nailing

- Closed locked nailing was chosen for this difficult fracture pattern in a patient with multiple medical comorbidities
- Proximal fixation is achieved via a spiral blade

Interlocked Nails: Outcomes

- Antegrade insertion resulted in loss of shoulder motion in 6% to 36% of cases
  - Less shoulder pain with anterior acromial approach compared to lateral deltoid splitting approach
- Retrograde insertion seems to give a more predictable long-term function without elbow dysfunction provided no associated injuries in same extremity
- Nonunion has been noted in 0% to 8% of locked IMN of humeral shaft fractures

Interlocked Nails: Outcomes

- Rates of delayed union are as high as 20%
- Malunion, hardware failure, and iatrogenic nerve palsy are all uncommon in series of humeral shaft fractures treated with interlocking nails

External Fixation: Indications

- Severe open fractures with extensive soft-tissue injury or bone loss
- Associated burns
- Infected nonunions
- Humeral shaft fracture with neurovascular injury

External Fixation: Techniques

- Attention to safe zones for pin placement is recommended
- Open insertion techniques are utilized to minimize neurovascular injury
- Meticulous pin care, stable frame constructs, and liberal use of bone grafting can reduce the problems associated with external fixation

External Fixation: Techniques

- Fixator can be used provisionally with conversion to internal fixation or functional bracing after any associated soft-tissue problems are resolved

External Fixation

- A unilateral frame was used to align this comminuted fracture is a patient with extensive soft tissue injury
- Healing occurred with callus

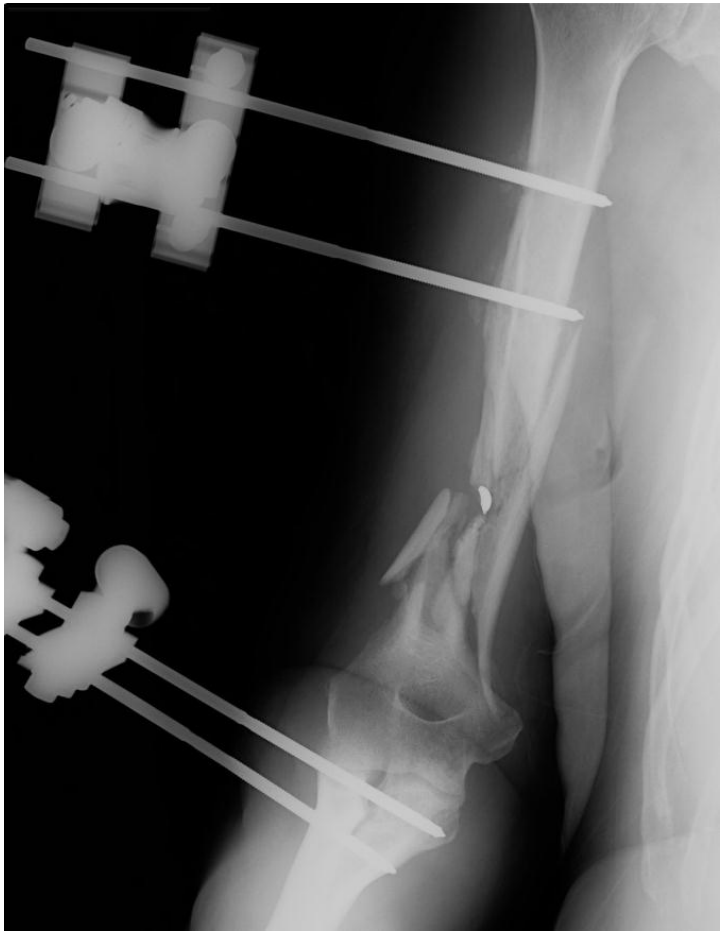

External Fixation: Outcomes

- Function reported as good or excellent in 70% of patients in one large series
- Average arc of elbow ROM was 90 degrees
- Worse results were encountered in patients with concomitant multiple nerve injuries and intra-articular fracture extension

External Fixation: Outcomes

- Complications cited in one large series included:
  - delayed union and malunion
  - pin tract infection and formation of pin tract sequestra
  - late fracture secondary to another major trauma

Complications of Humeral Shaft Fractures

- Radial nerve injury
- Vascular injury
- Nonunion

Radial Nerve Injury

- Incidence varies from 1.8% to 24% of shaft fractures
- Primary - occurs @ injury
- Secondary - occurs later during closed or open management
- Mangement controversial

Radial Nerve Injury

- Transverse fractures of the middle 1/3 are most commonly associated with neuropraxia
- Spiral fractures of the distal 1/3, the Holstein-Lewis fracture, present a higher risk of laceration or entrapment of the radial nerve

Radial Nerve Injury

- Spontaneous recovery of nerve function is found in >70% of reported cases
- Even secondary palsies, those associated with fracture manipulation, have a high rate of spontaneous recovery
- 90% will resolve in 3 to 4 months
- EMG and nerve conduction studies can help to determine the degree of nerve injury and monitor the rate of nerve regeneration

Preferred Management of Fractures with Associated Radial Nerve Palsy

- Three most frequently stated indications for immediate surgical management for fractures associated with radial nerve palsy are:
  - open fractures
  - Holstein-Lewis fractures
  - Secondary palsies developing after a closed reduction

Preferred Management of Fractures with Associated Radial Nerve Palsy

- Exploration for palsies associated with open fracture is the only indication that is not associated with conflicting data
- For secondary palsies, but it is not clearly established that surgery will improve the ultimate recovery rate compared to nonsurgical management

Preferred Management for Fractures with Primary Palsy

- If open, exploration indicated
- In a review of 50 cases of primary and 16 secondary palsies all observed initially, there was no difference noted in recovery rates for lesions that required neurorrhaphy between early or delayed exploration
- Early exploration may risk additional injury to nerve if it is only contused
- Conclusion: Nonsurgical fracture management is indicated initially

Advantages of Late Versus Early Nerve Exploration

- Enough time will have passed for recovery from neuropraxia or neurotmesis
- Precise evaluation of a nerve lesion is possible
- The associated fracture will(may) have united
- The results of secondary repair are as good as those of primary repair

Vascular Injury

- Although uncommon, injury to the brachial artery can occur
- Mechanisms include:
  - Gunshot wound
  - Stab wound
  - Vessel entrapment by fracture fragments
  - Occlusion after hematoma or swelling in a tight compartment

Vascular Injury

- Brachial artery has the greatest risk for injury in the proximal and distal 1/3 of arm
- Role of arteriography in evaluation of long bone fractures with vascular compromise remains controversial
- Unnecessary delays for studies of equivocal value are imprudent in the management of an ischemic limb

Vascular Injury

- Arterial inflow should be emergently established within 6 hours
- At surgery, the vessel should be explored and repaired and the fracture stabilized
- If limb viability is not in jeopardy, bone repair may precede vascular repair
- External fixation should be considered an option

Nonunion

- Rate for humeral shaft fractures ranges from 0% to 15%
- Proximal and distal aspects of the humerus are at greatest risk for nonunion

Nonunion

- Caused by biologic and mechanical factors including:
  - significant bone gaps secondary to fracture distraction, soft-tissue interposition, or bone loss
  - uncontrolled fracture motion
  - impaired soft-tissue envelope and blood supply
  - infection

Nonunion: Predisposing Factors

- transverse fracture pattern
- older age
- poor nutritional status
- osteoporosis
- endocrine abnormality affecting calcium balance
- use of steroids
- anticoagulation
- previous RT

Nonunion: Treatment Goals

- Obtain osseous stability
- Elimination of nonunion gap
- Maintain or restore osseous vascularity
- Eradication of infection

Nonunion: Surgical Treatment

- Stable internal fixation is the treatment of choice for most nonunions
- Compression plate fixation provides favorable results overall while IM fixation has been less successful
- Biologic stimulation with drilling, shingling and autografting is and important adjunct to internal fixation, especially for atrophic nonunions

Infected Nonunions: Surgical Treatment

- Require additional attention to complete debridement of all pathologic tissue
- May benefit from antibiotic bead placement
- May require provisional external fixation
- When the infection has been defined and controlled, definitive management may then require additional bone grafting and internal fixation

Complex Nonunions

- Nonunions associated with significant bone loss, synovial cavities, or failed prior surgical procedures
- These may require more elaborate reconstructive efforts
- Vascularized fibular transfers, intramedullary fibular grafting, and even Ilizarov techniques may be applicable

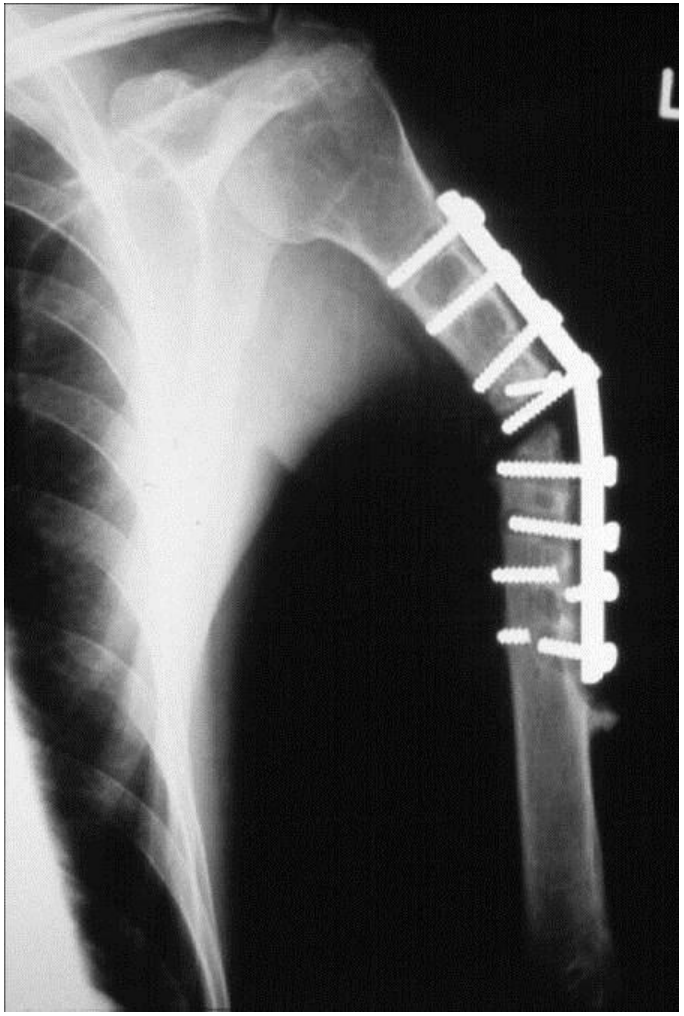

Infected Nonunion

- This infected nonunion was initially managed with radical debridement and insertion of antibiotic impregnated cement beads

Infected Nonunion

- Following appropriate antibiotic therapy, ORIF with abundant autograft was performed
- Healing slowly occurred

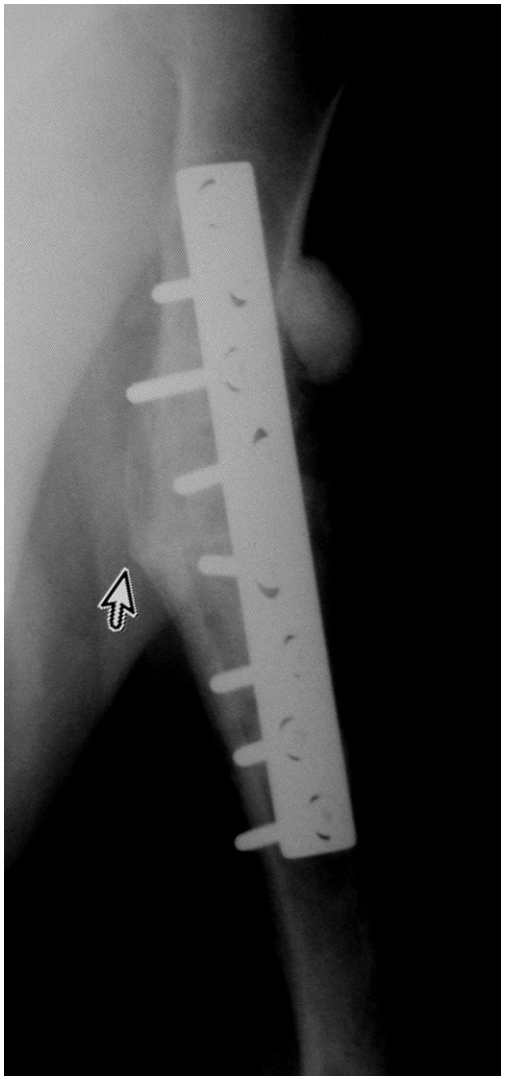

Thank You